

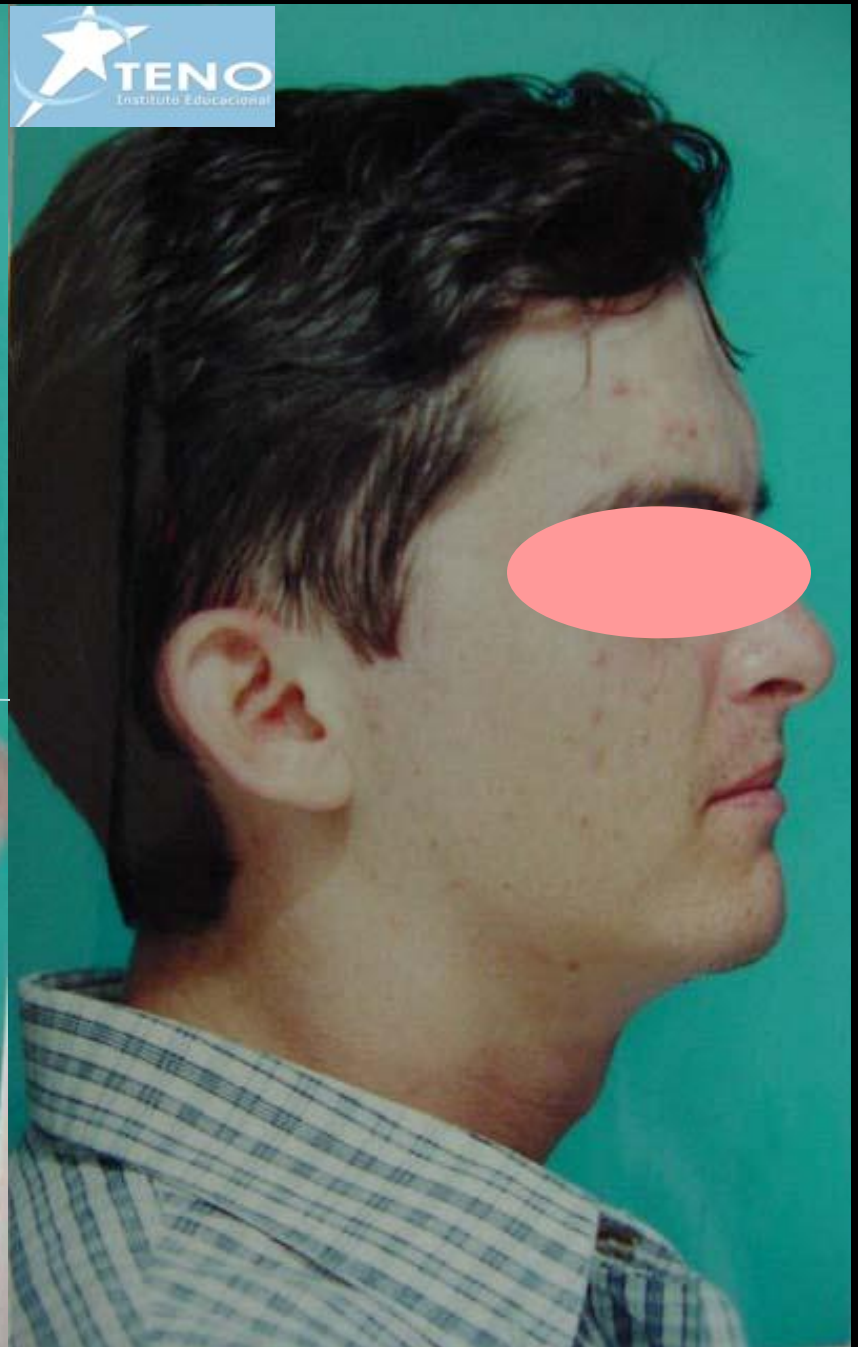
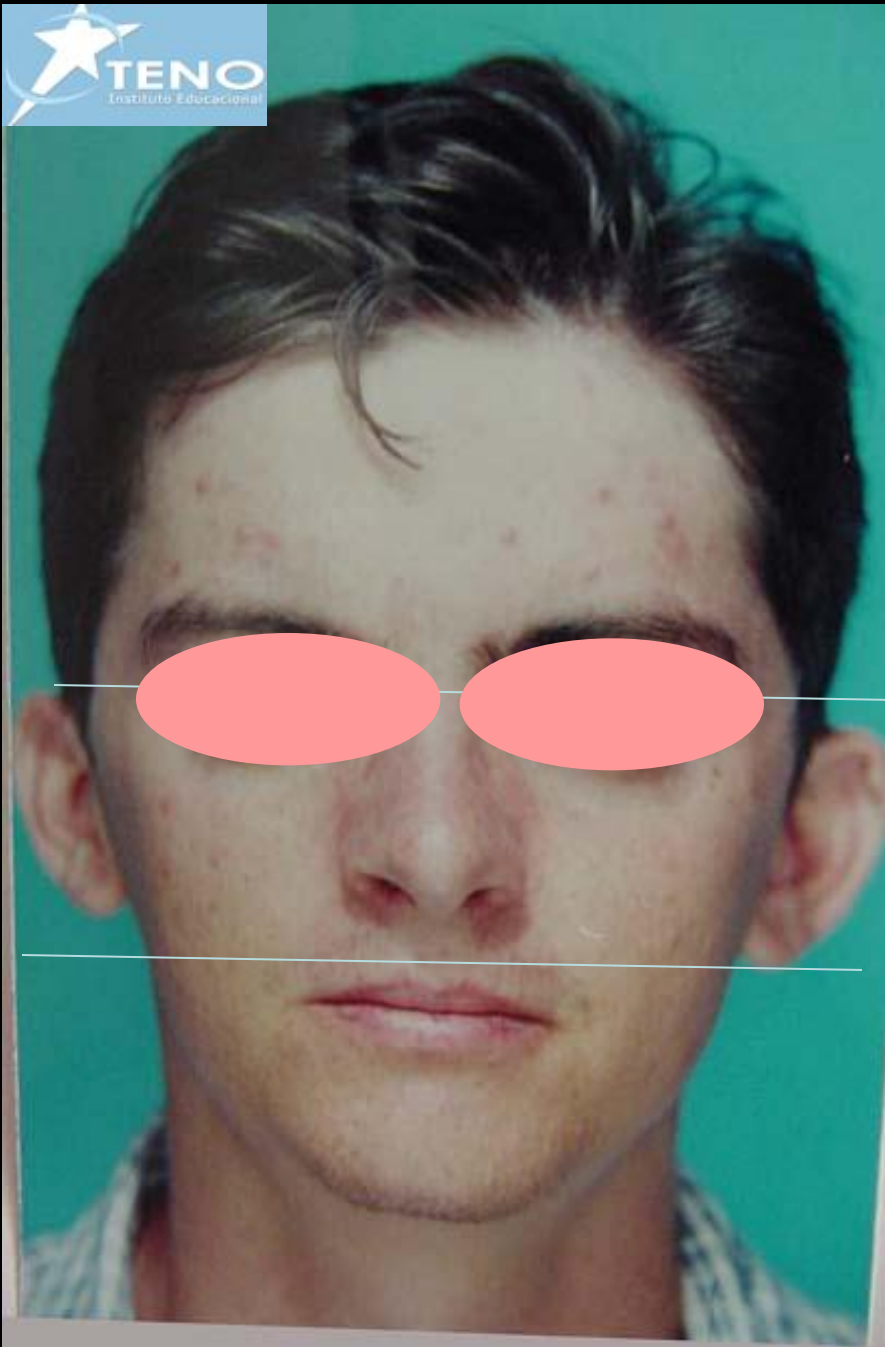
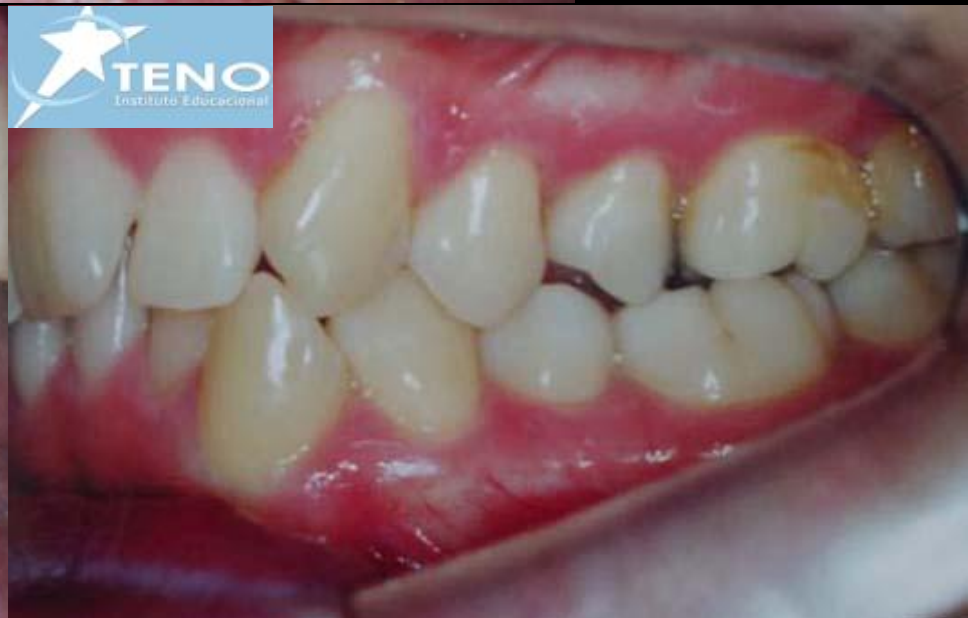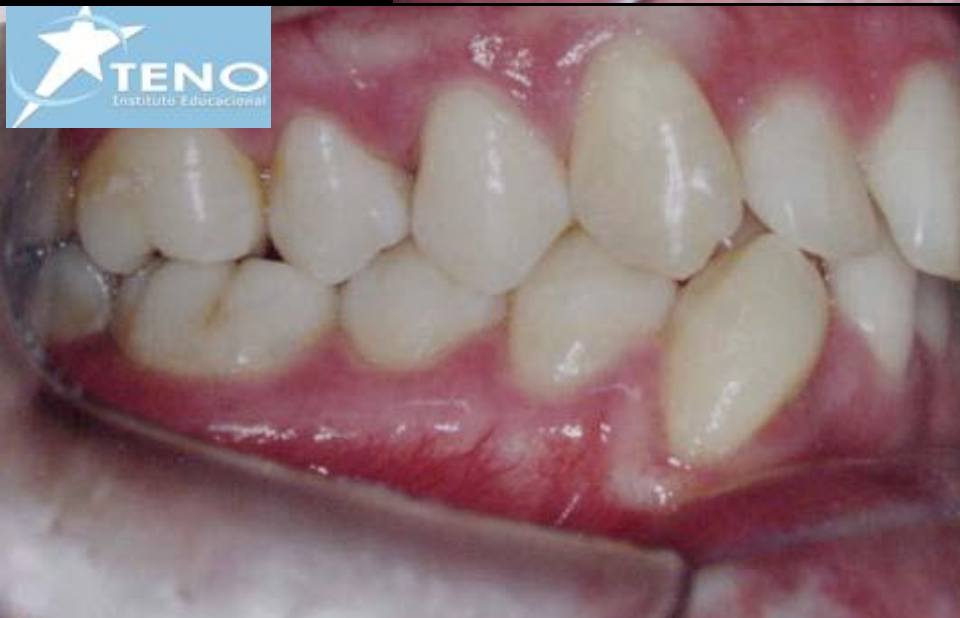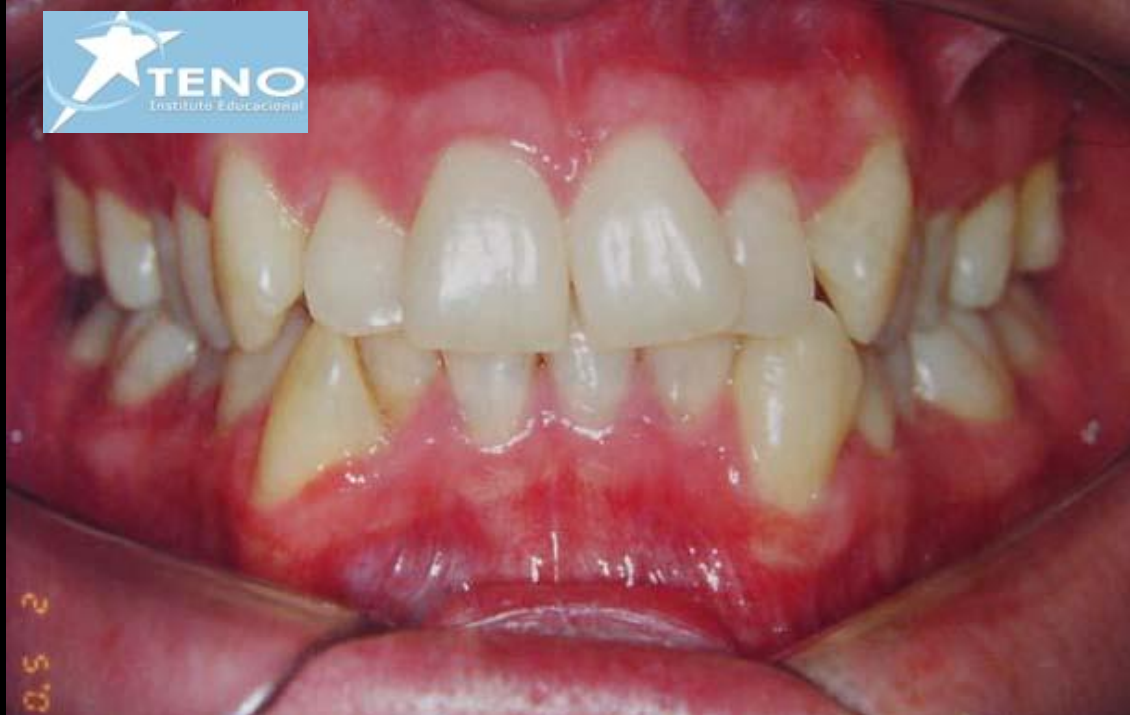## Caso cedido pelo Prof. Dr. Artênio Garbin

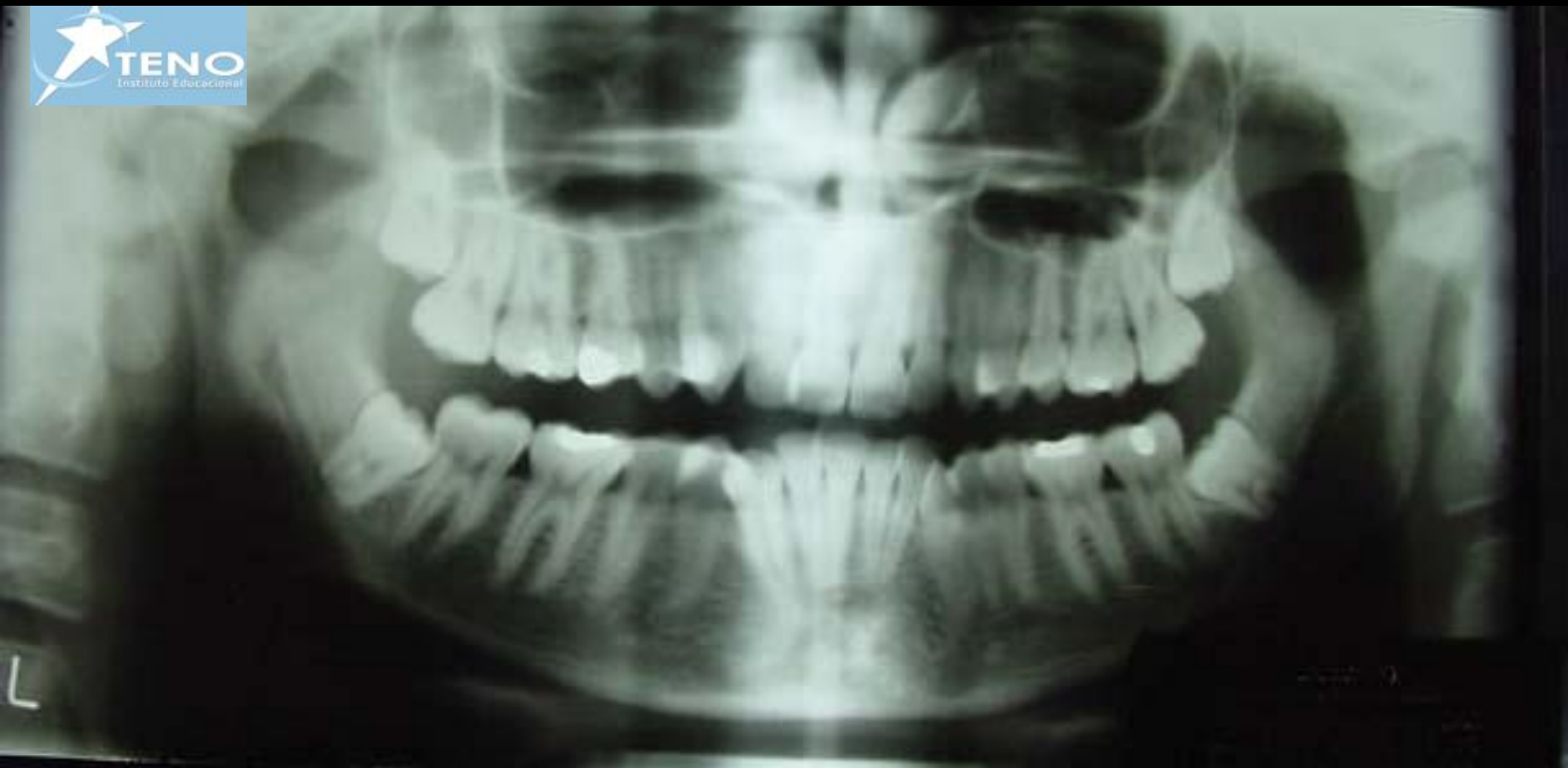Especialista em Ortodontia e Ortopedia Facial

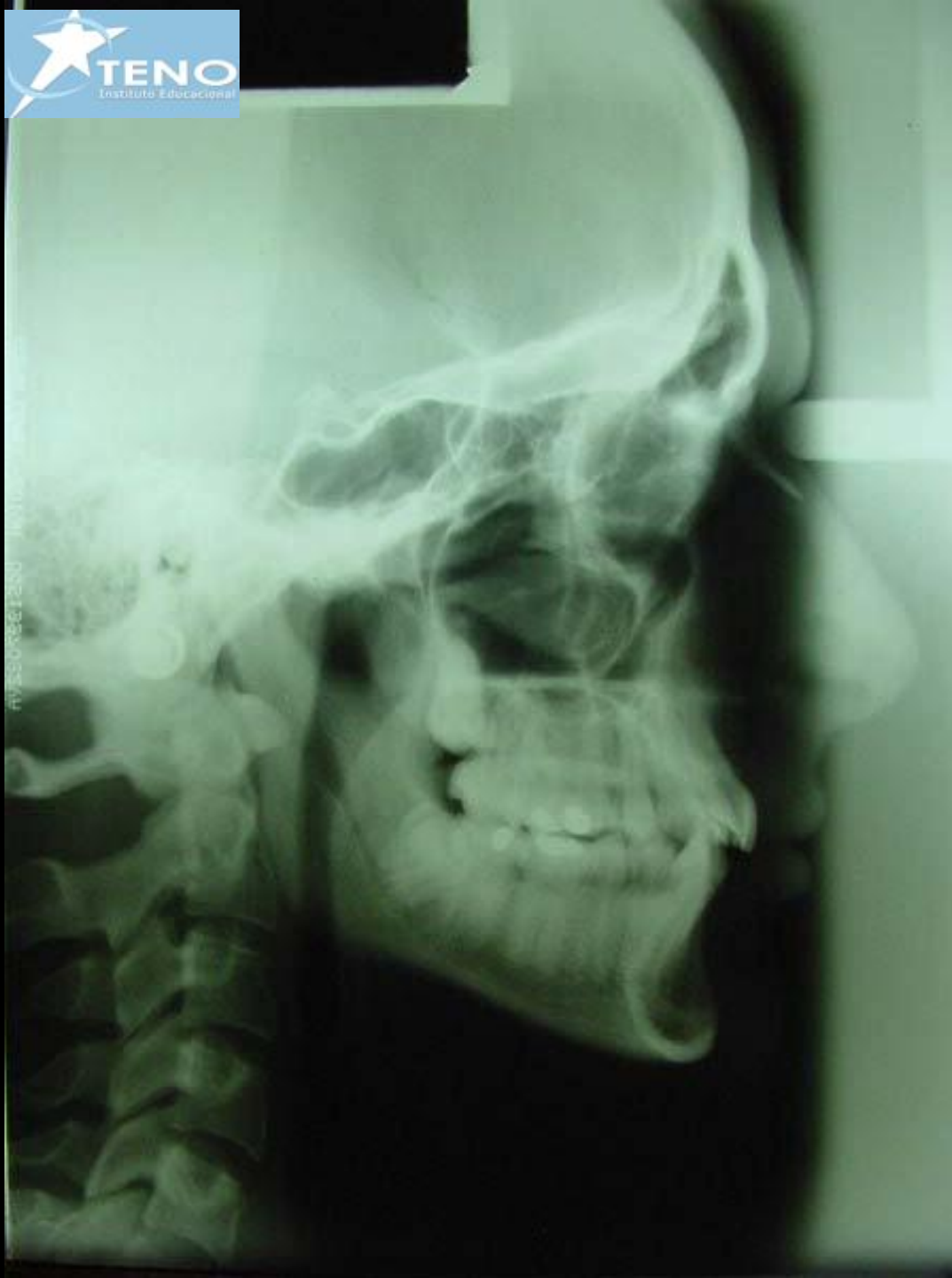- Mestre em Ortodontia e Ortopedia Facial - UNICAMP
- Doutor em Ortodontia e Ortopedia Facial - UNICAMP
- Professor convidado do curso de Especialização em Ortodontia e Ortopedia Facial da Universidade Cruzeiro do Sul.
- Professor convidado do curso de Atualização em Ortodontia e Ortopedia Facial da ABO - Regional Araçatuba
- Professor convidado do curso de Especialização em Ortodontia e Ortopedia Facial da ABO - Regional Araçatuba
- Professor Adjunto da Faculdade de Odontologia de Araçatuba - UNESP
- Professor de Ortodontia do Programa de Pós-graduação em Odontologia Preventiva e Social -FOA UNESP
- Coordenador da Pós-graduação de Odontologia Preventiva e Social - UNESP
- Presidente da ABO - Regional Araçatuba

Classe I apinhamento severo  
dentes bem posicionados,  
tratamento com QH e BH



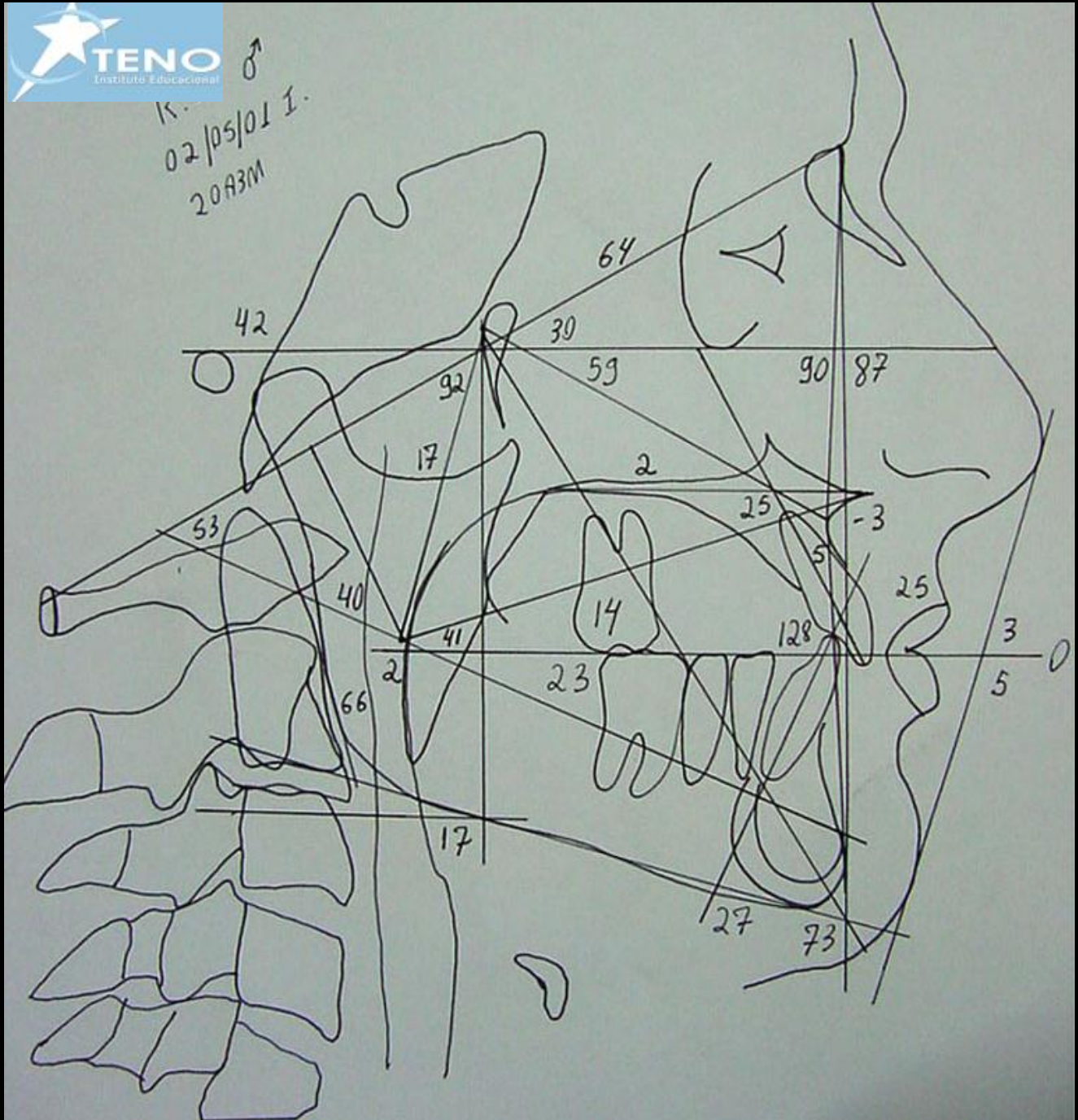


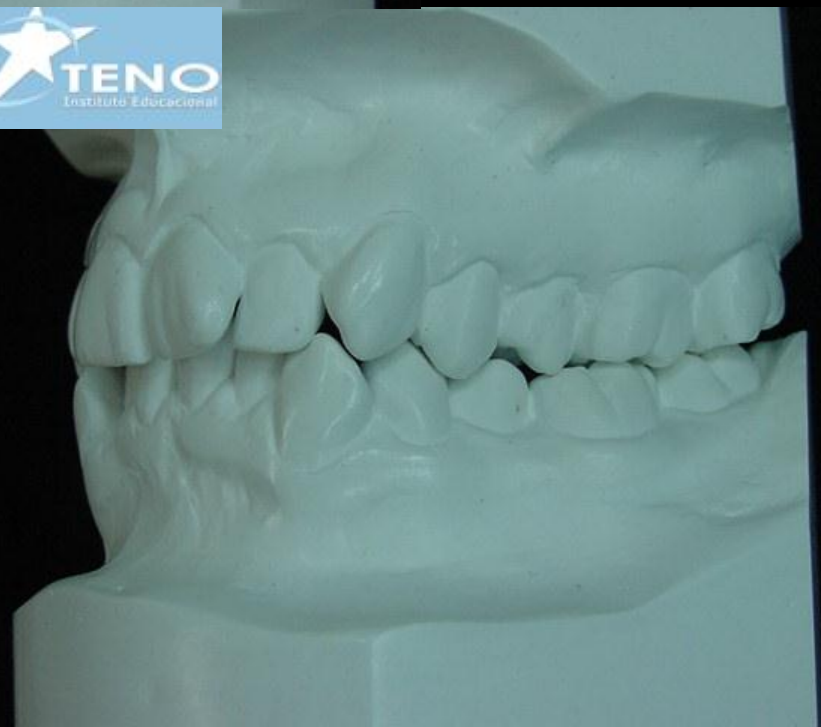
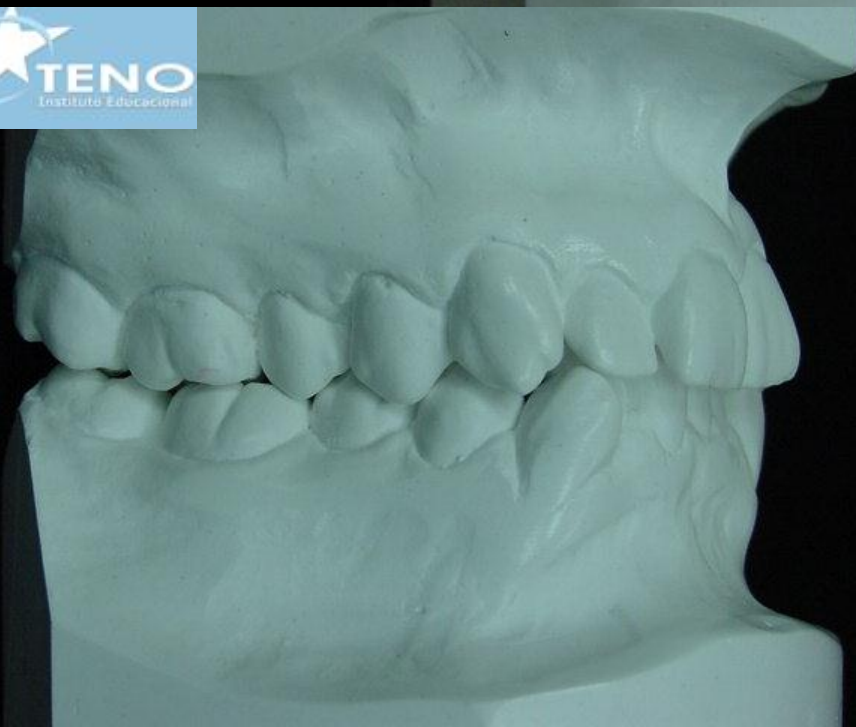
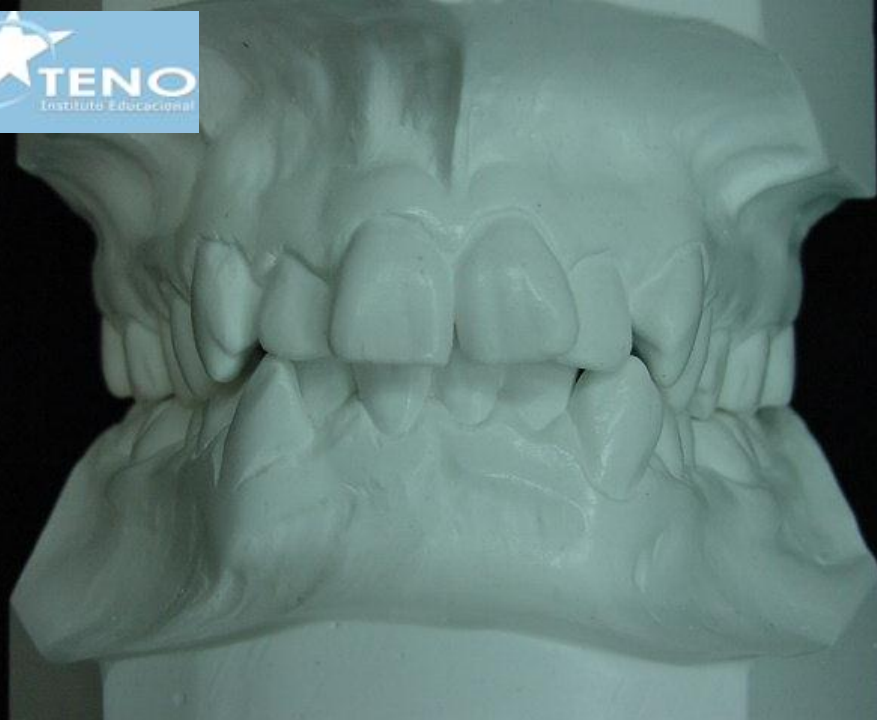

www.tenoa.edu.br

15. ♂  
02/05/01 I.  
20A3M





# Discrepância Total

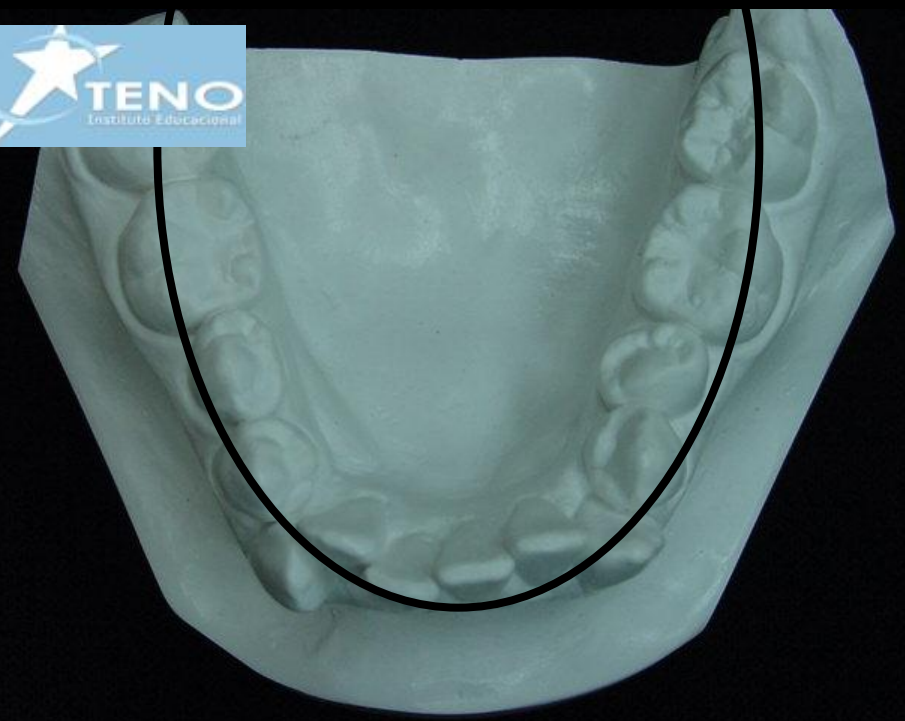
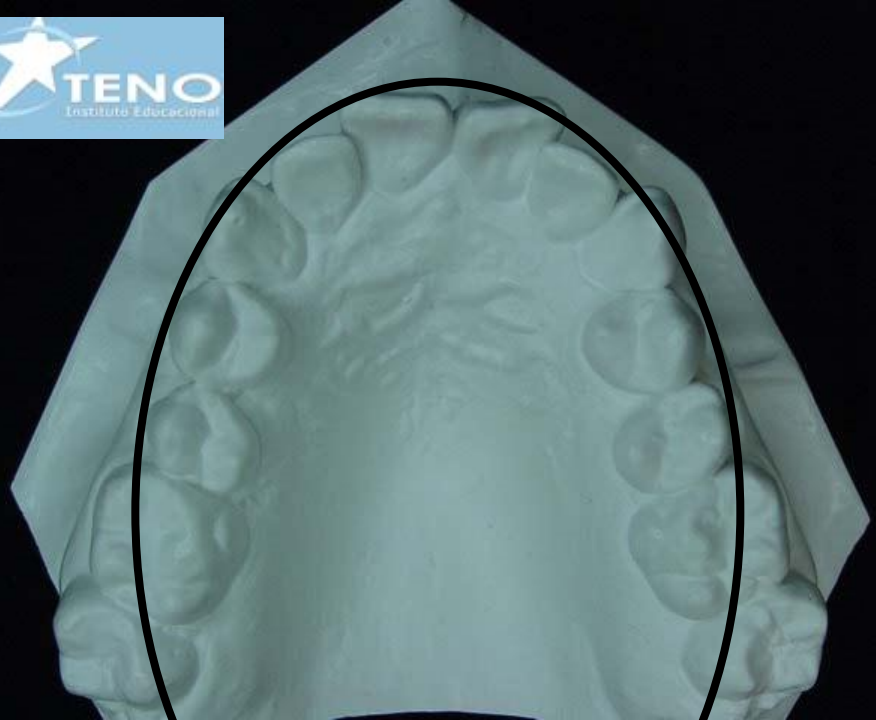

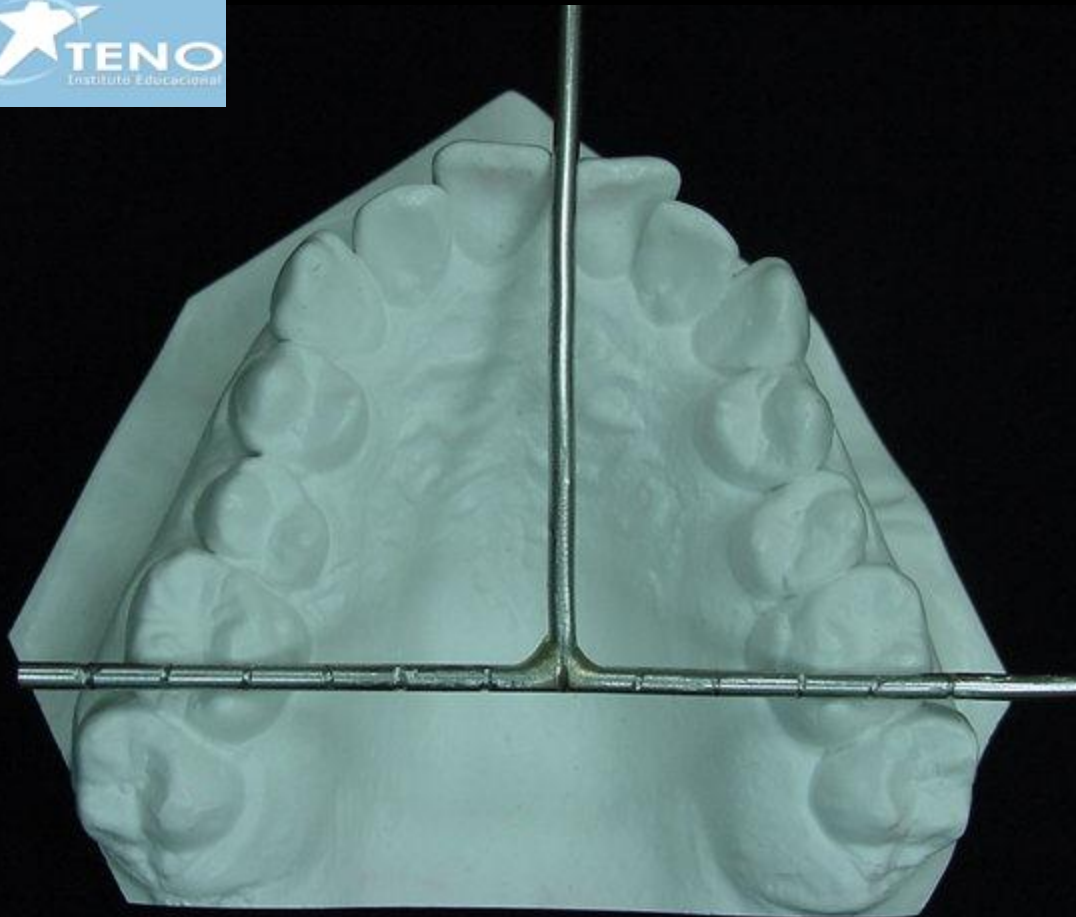
8.9 7.8 7.0 6.3 5.4 | 5.3 6.4 7.1 7.9 9.0

Total pré a pré inferior = 71.1 (Espaço requerido)

Tamanho fio latão = 63.0 (Espaço presente)

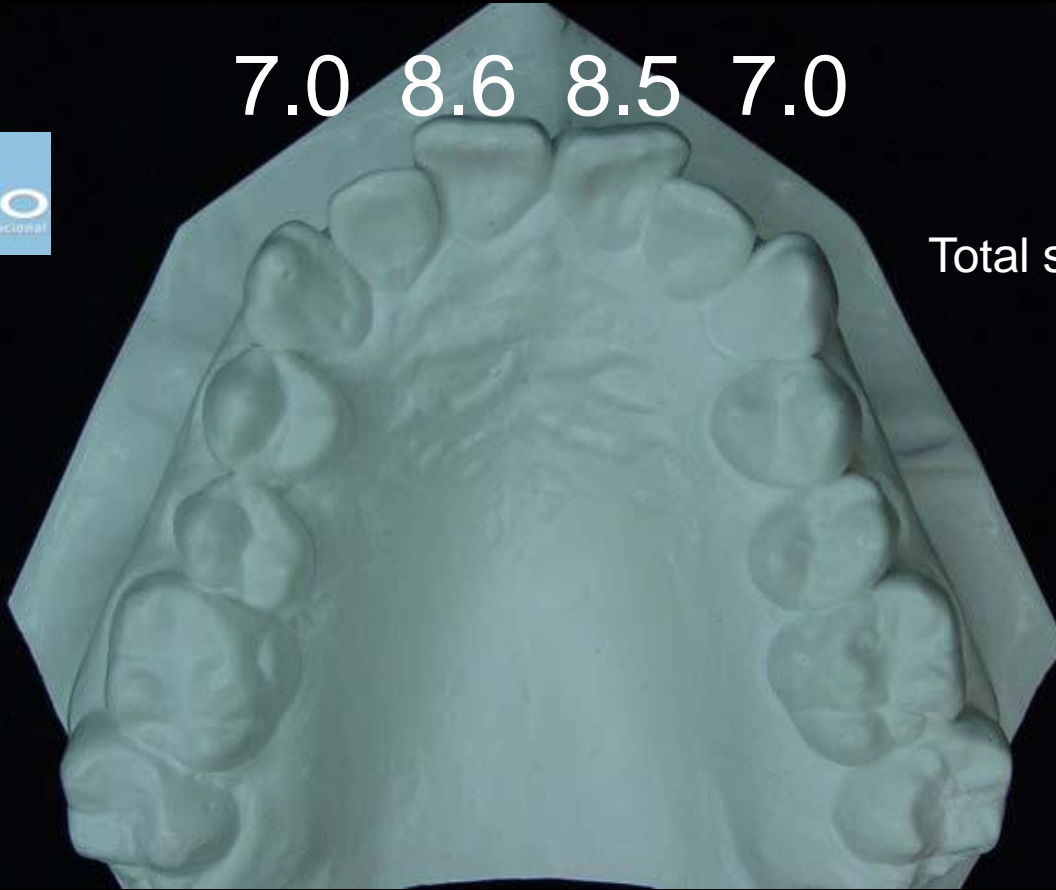
Diferença = 8.1 mm







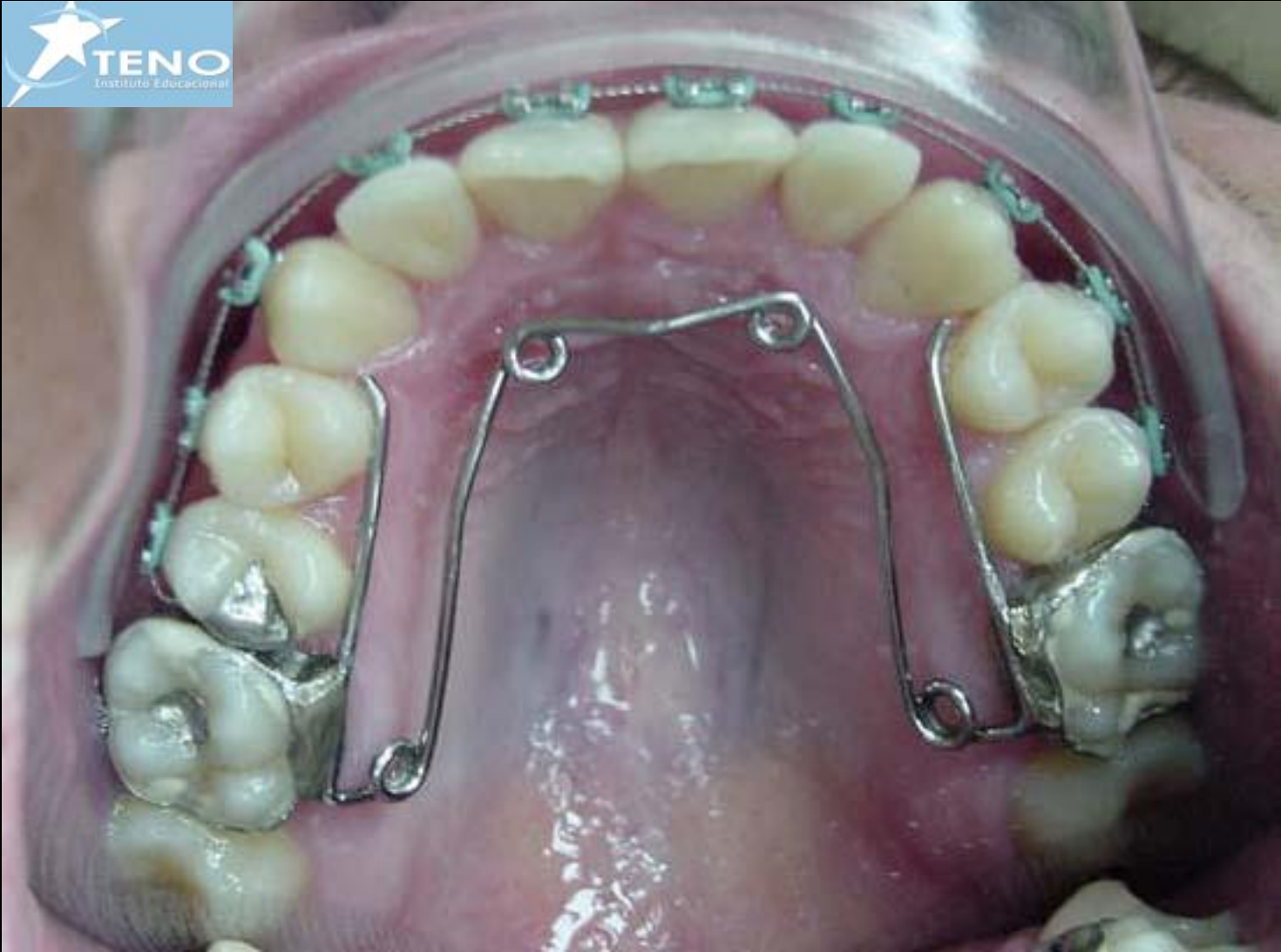7.0 8.6 8.5 7.0

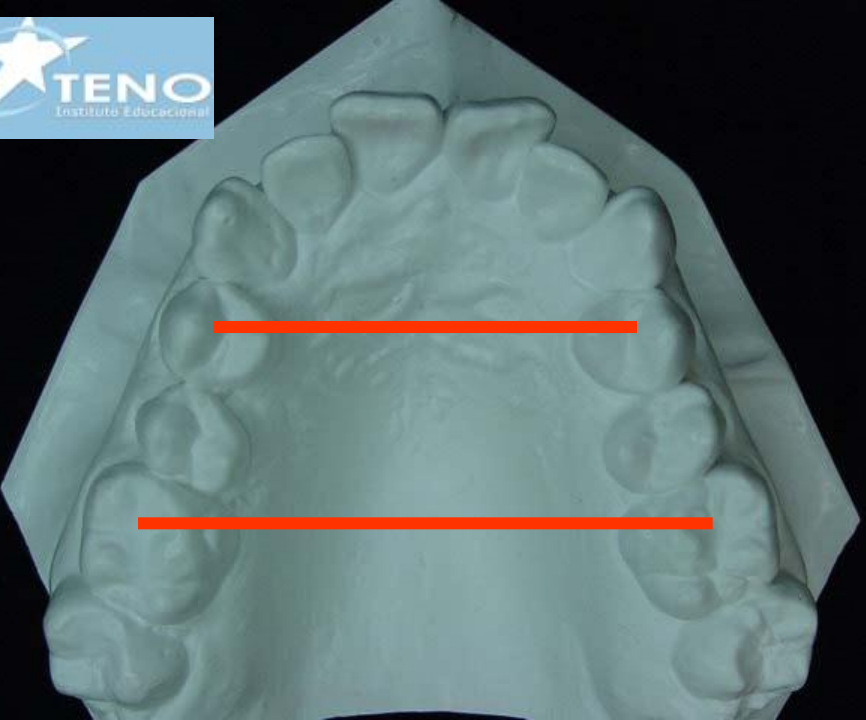


Total sup. = 31.1 mm

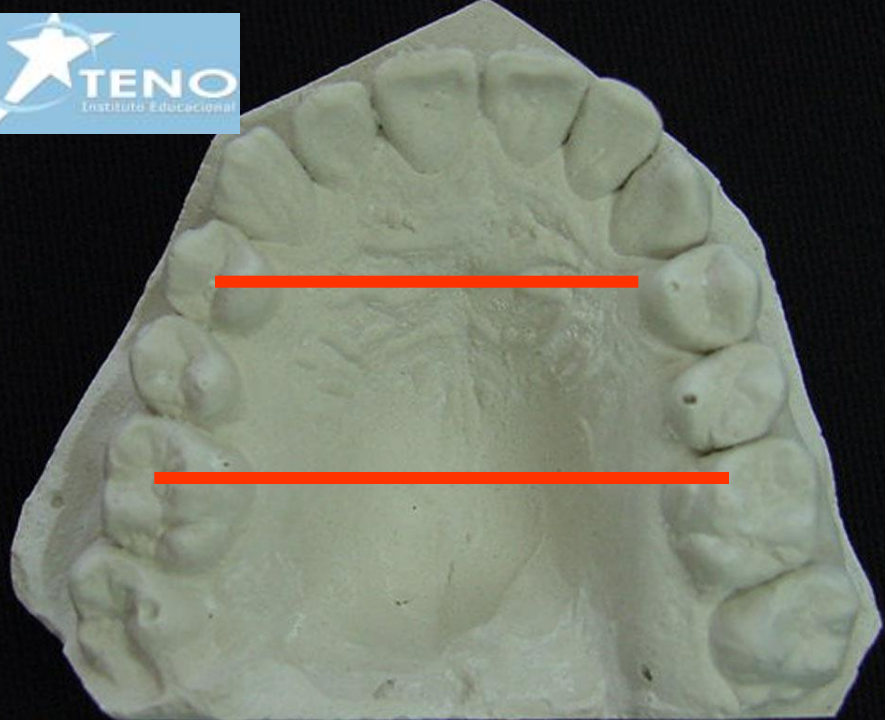
Índice de Pont

$$\frac{31.1 \times 100}{85} = 36.5 \quad \frac{31.1 \times 100}{65} = 47.8$$



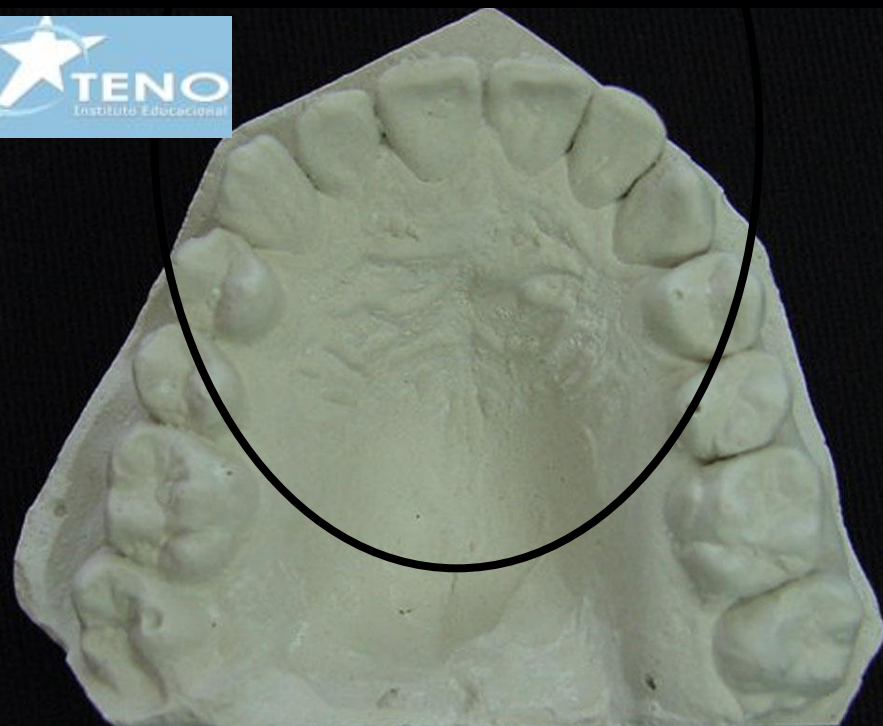
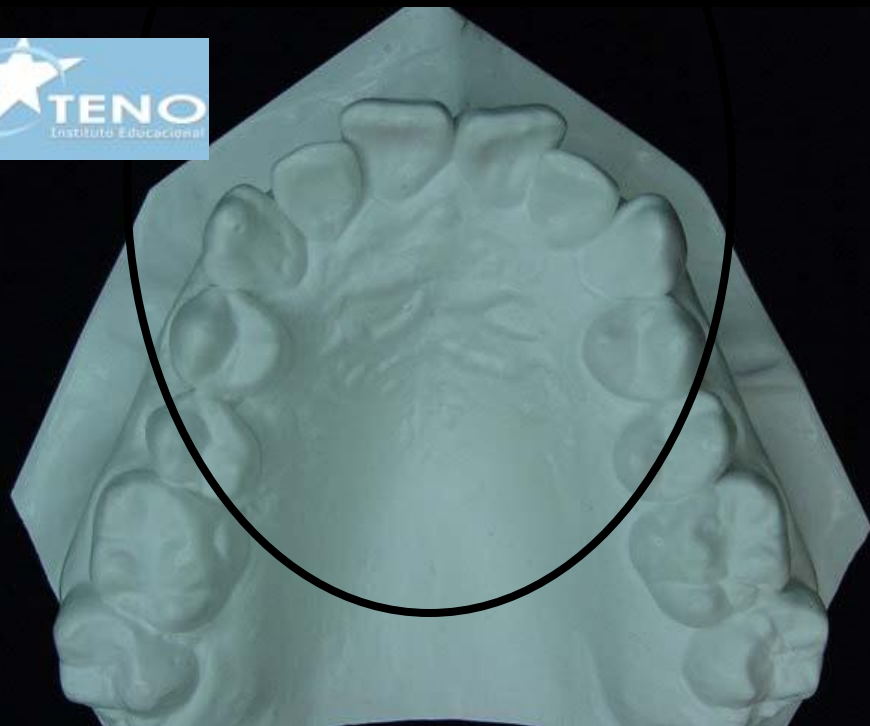


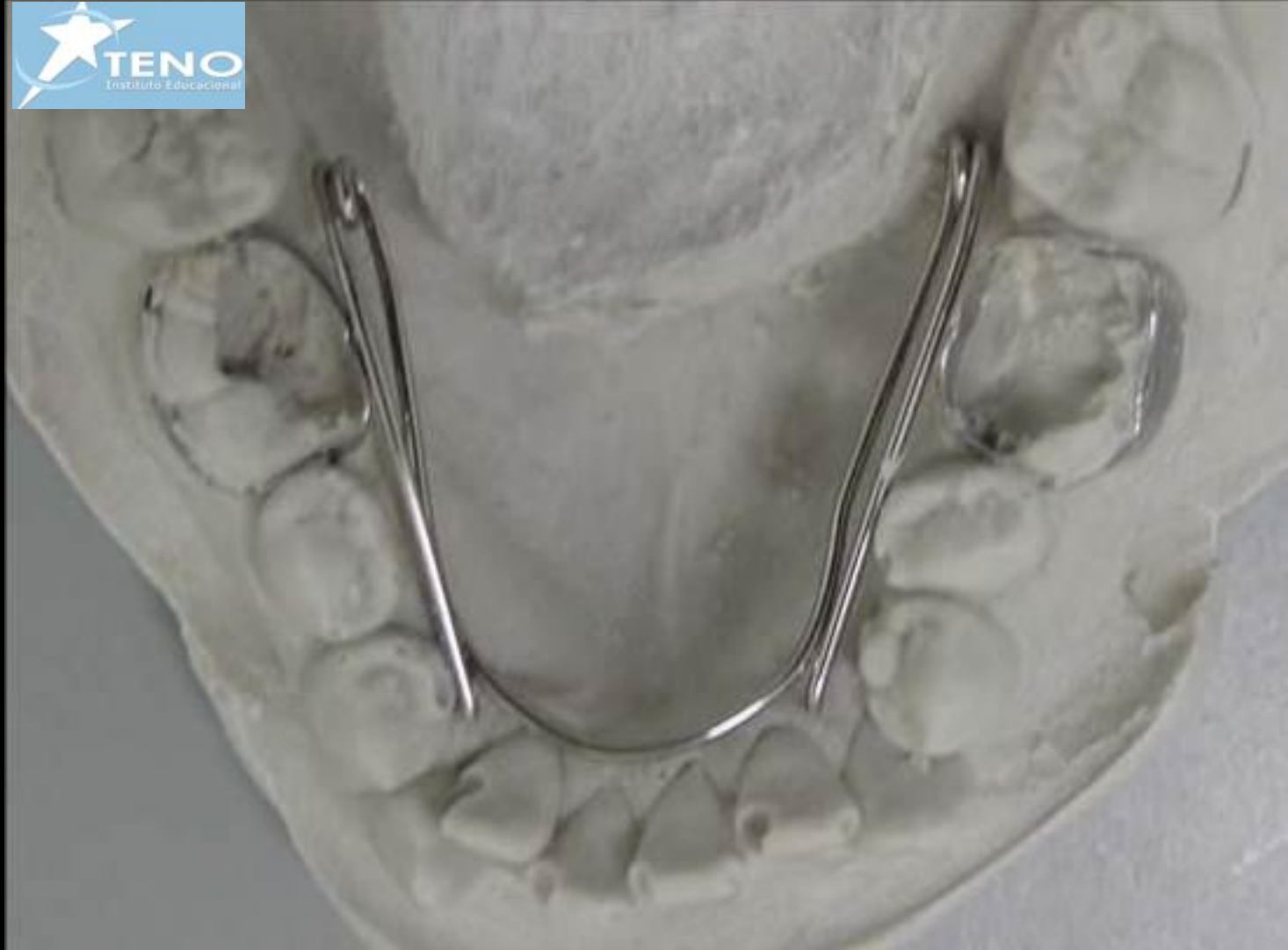AA = 30 mm  
AP = 43.5 mm

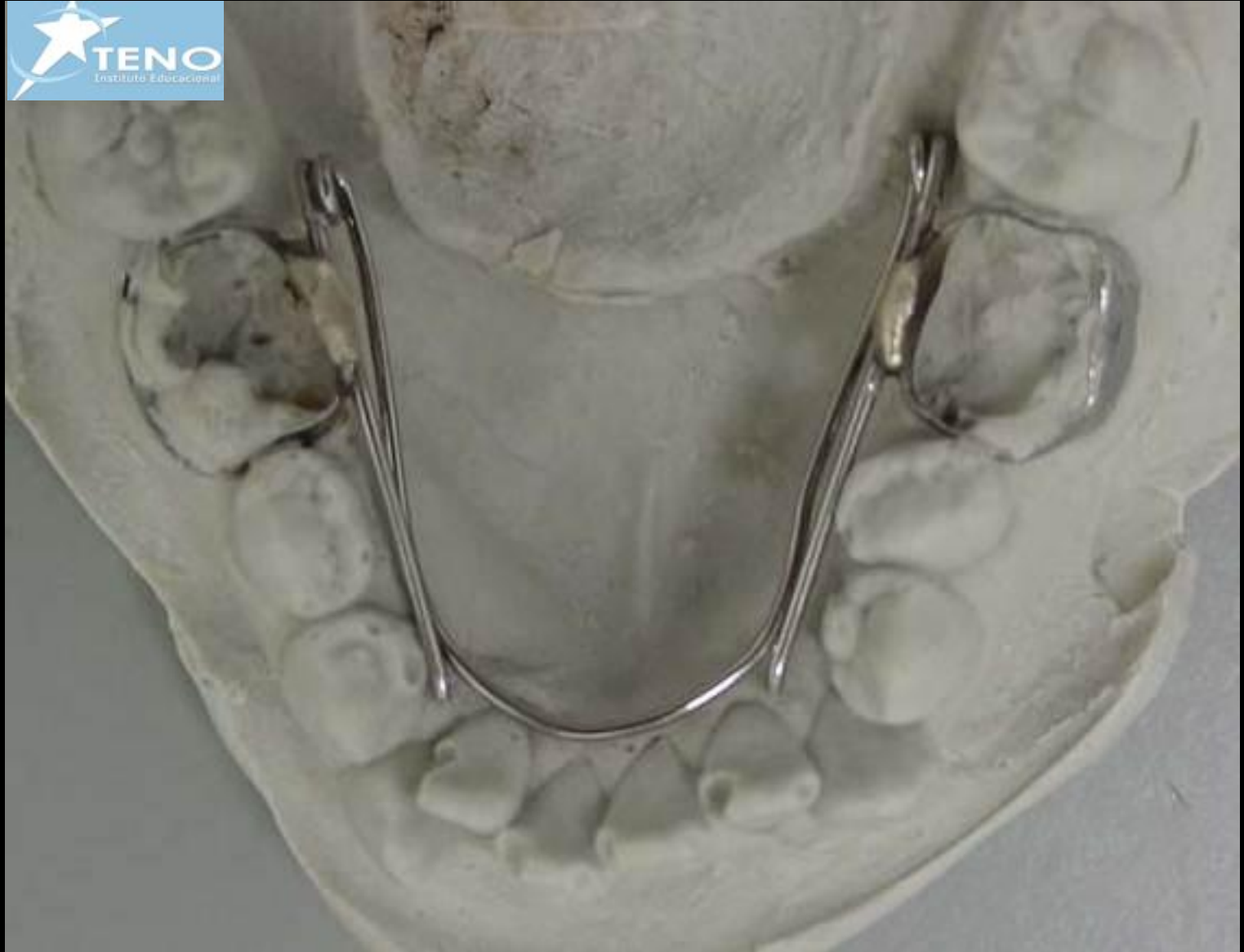

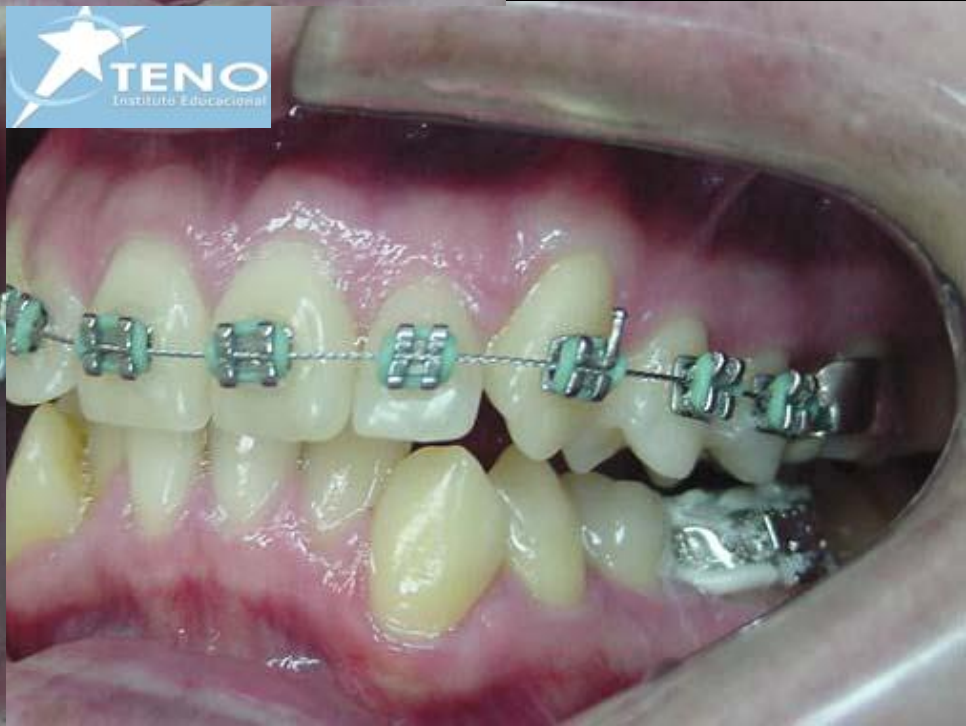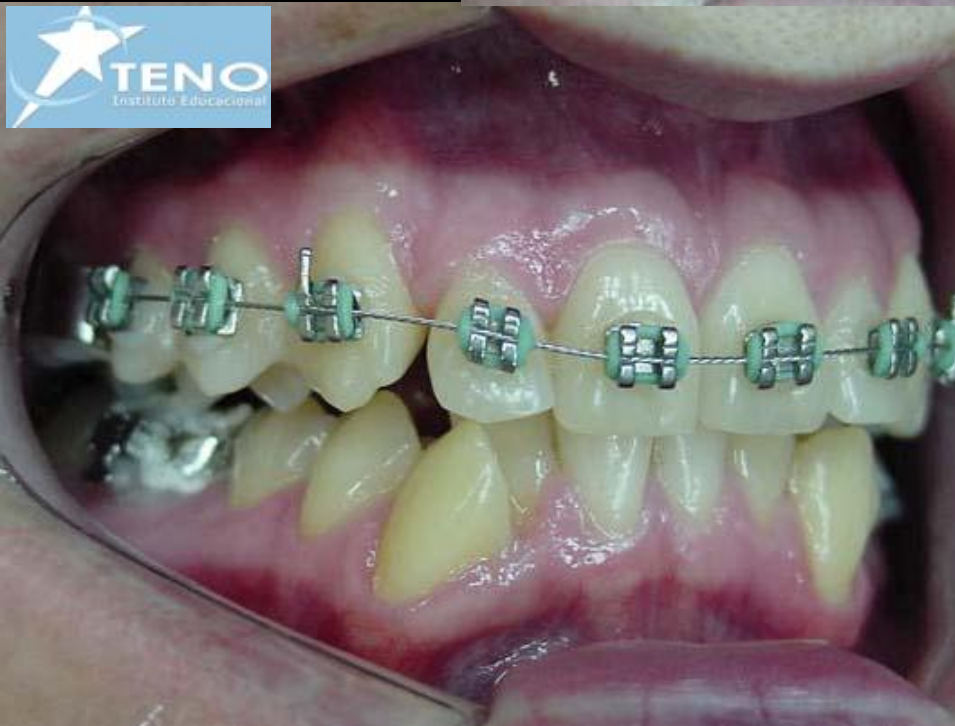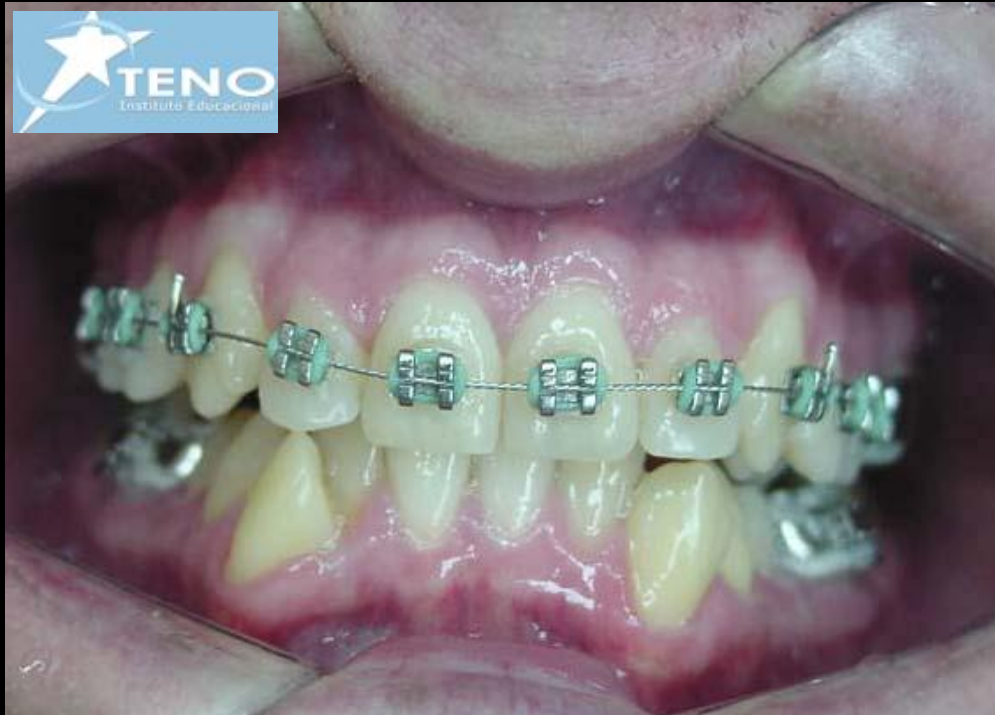AA = 36.5 mm  
AP = 46.5 mm

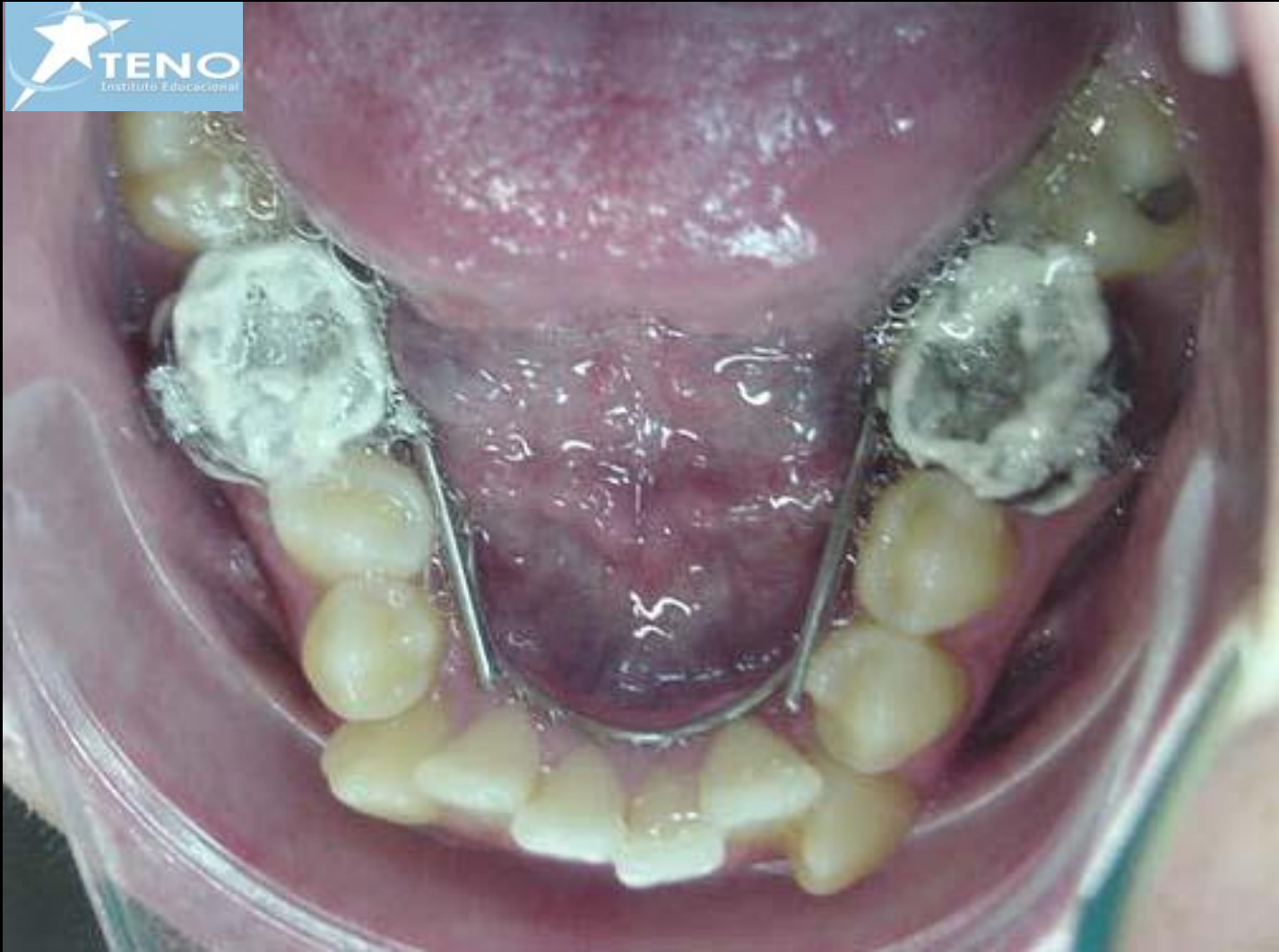Ideal  
36.5  
47.8

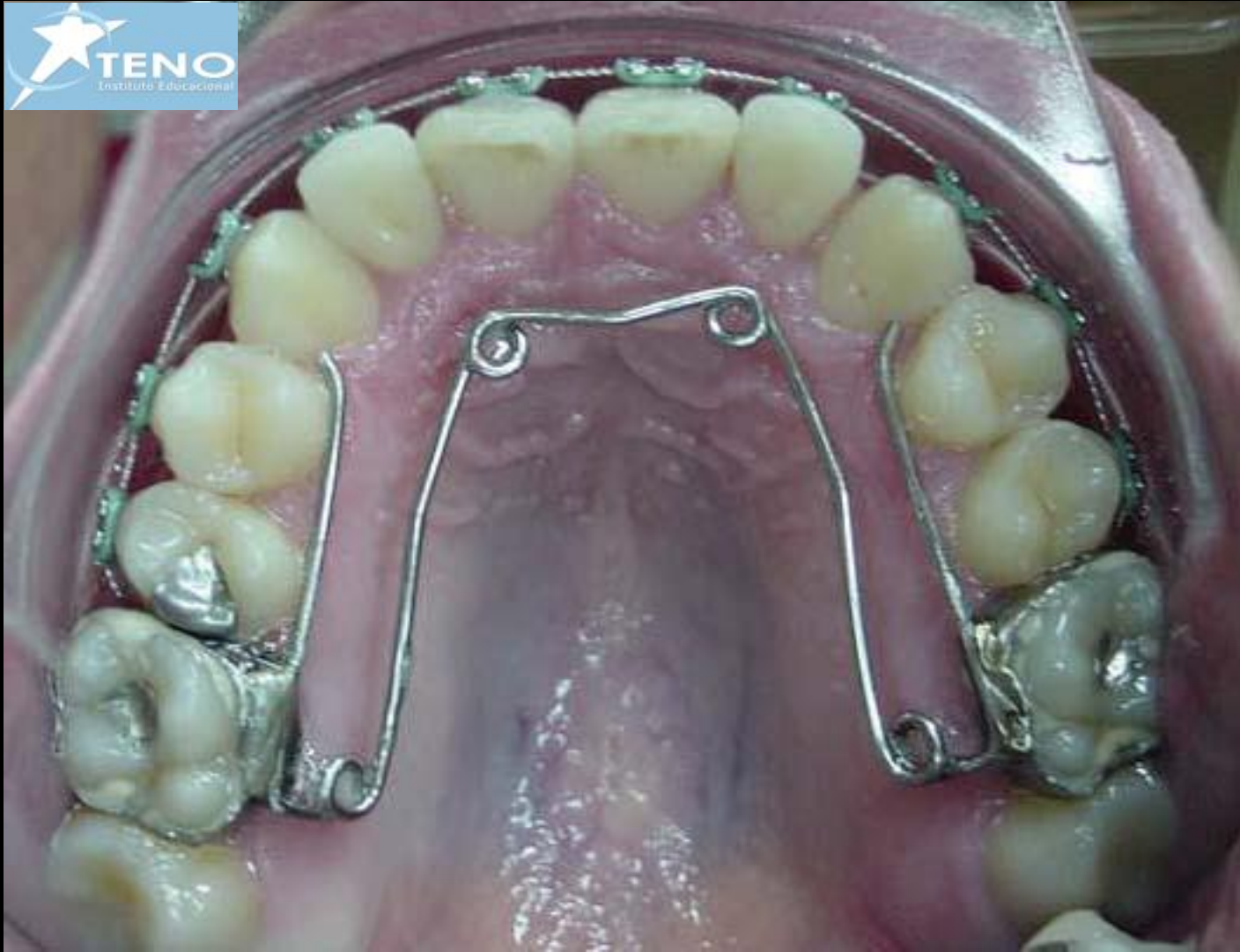


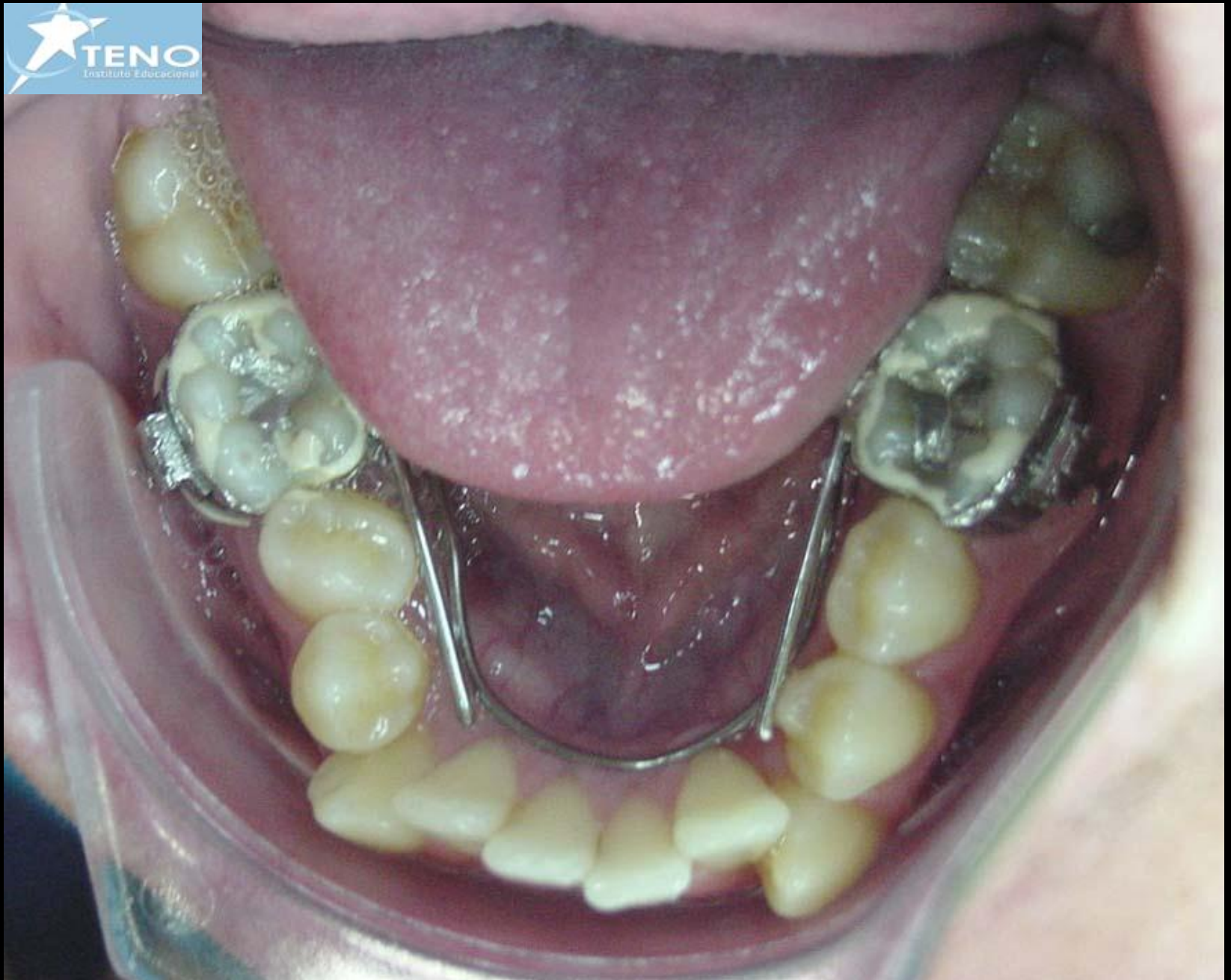


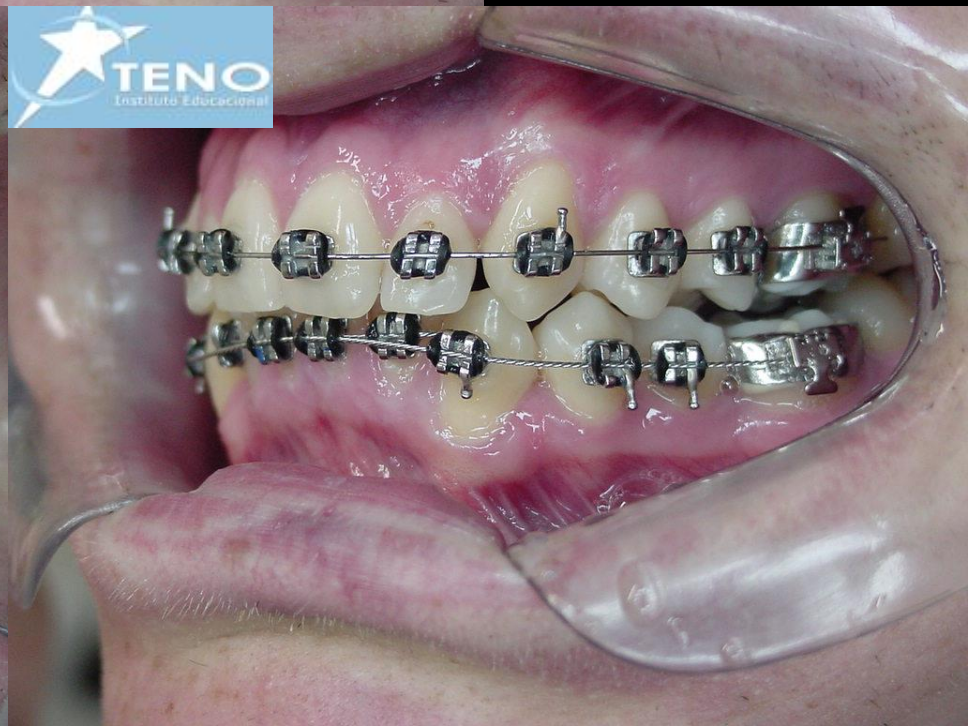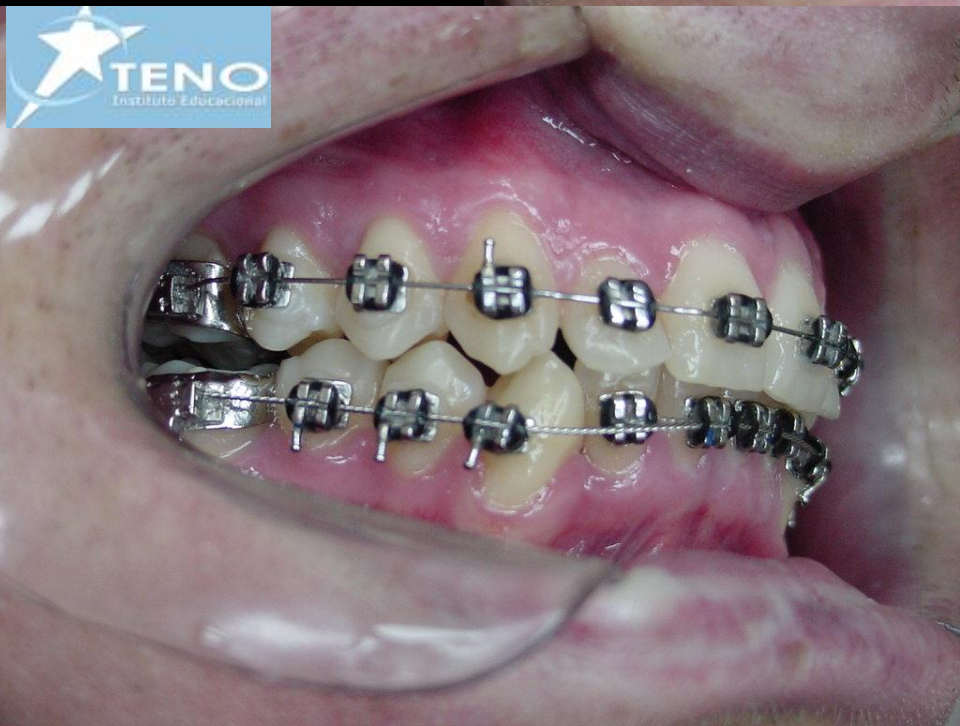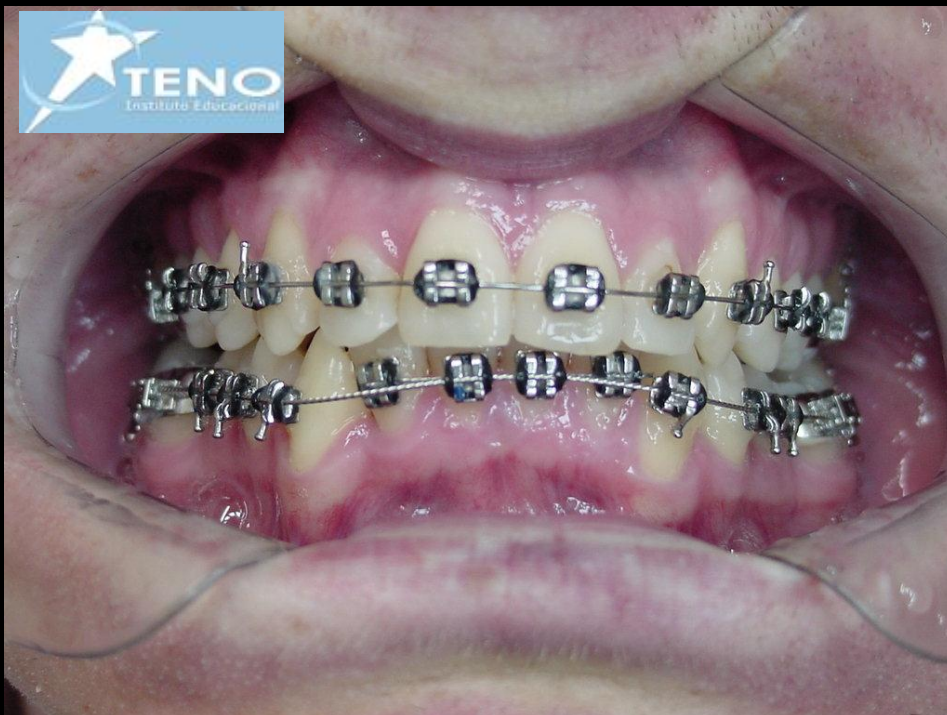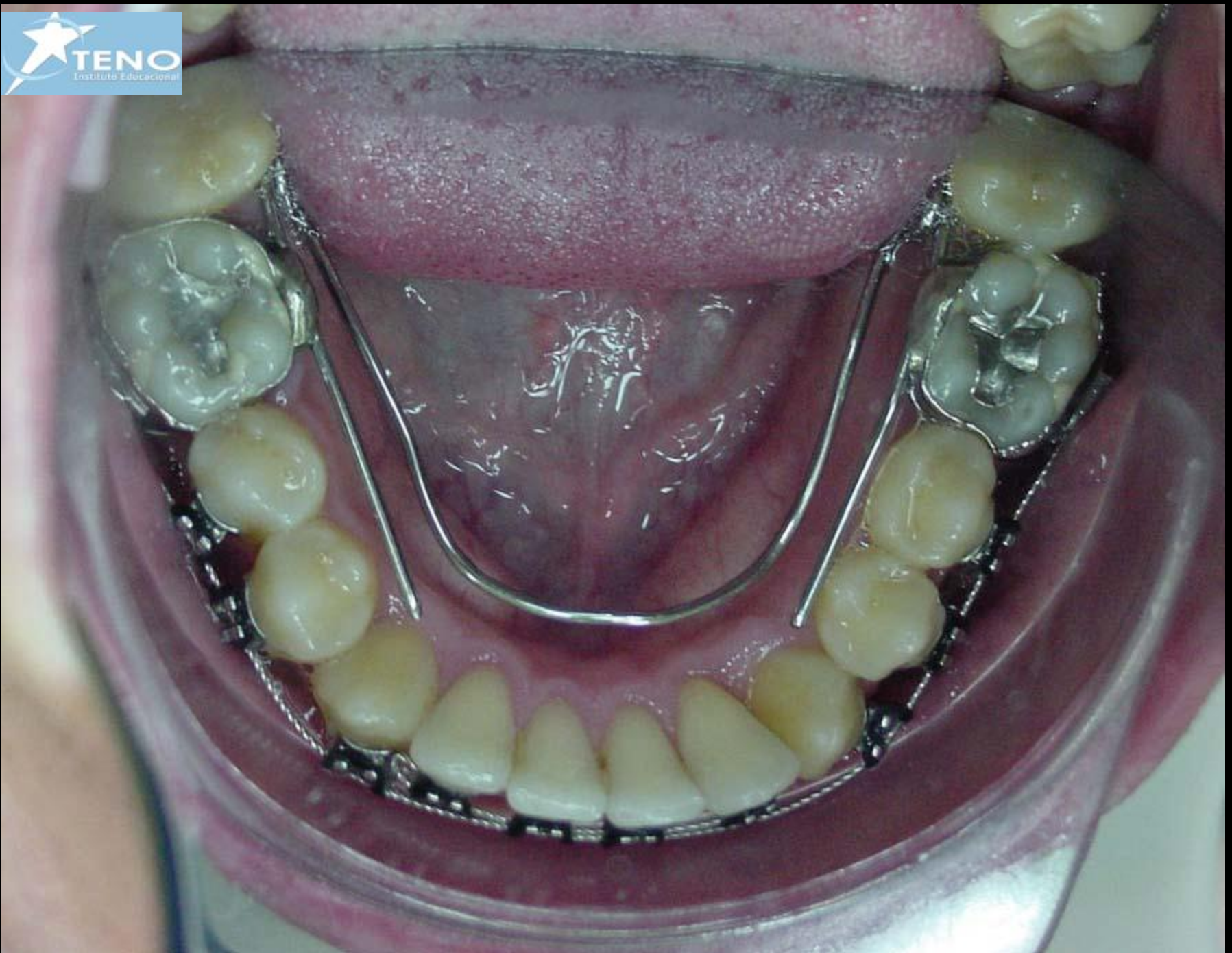


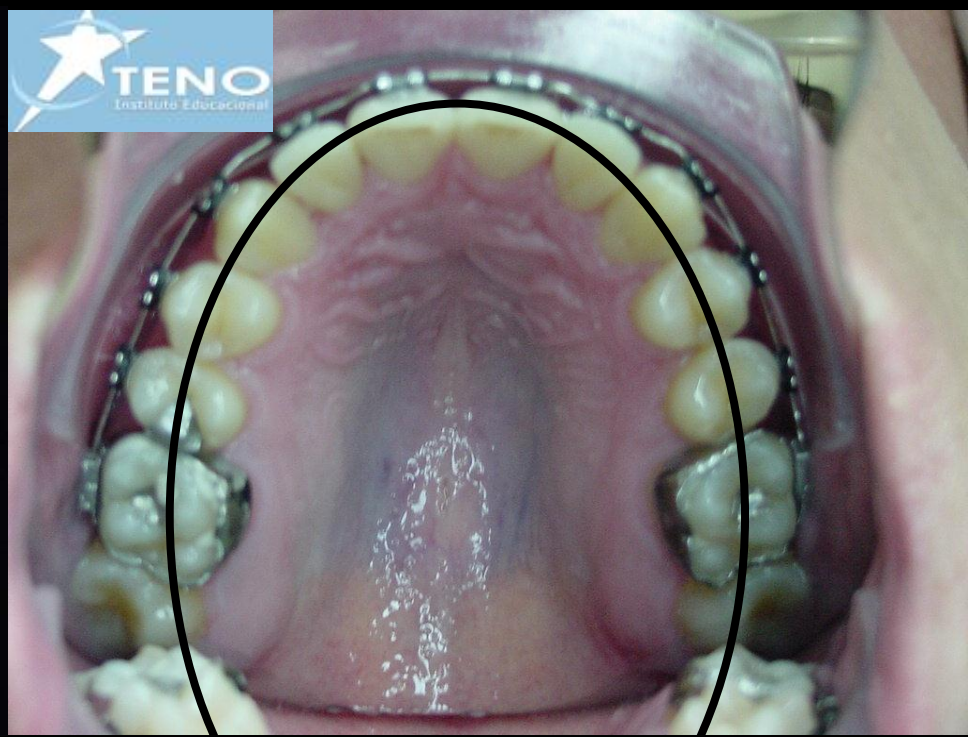
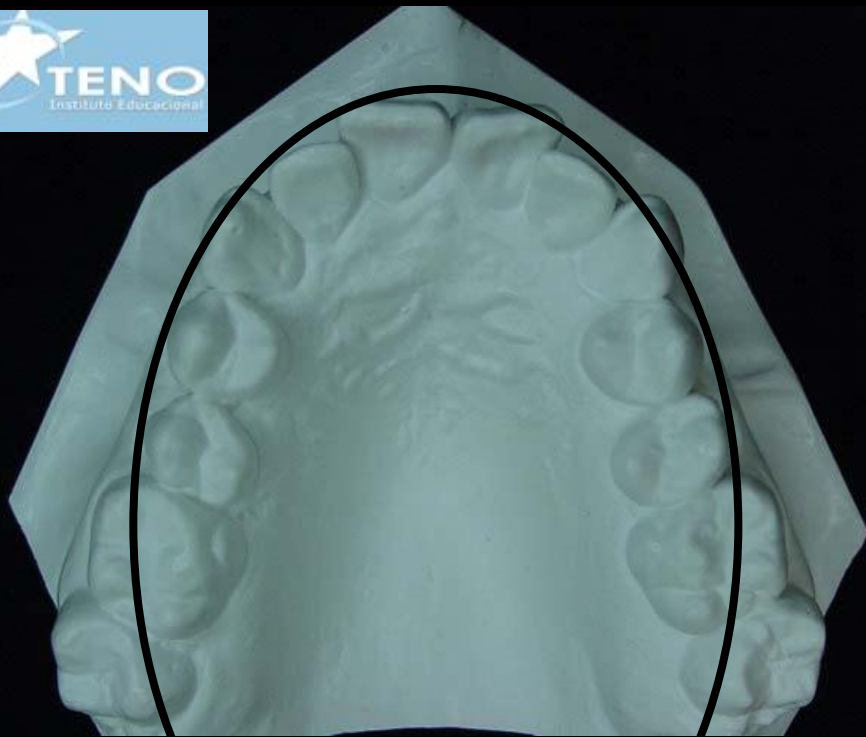


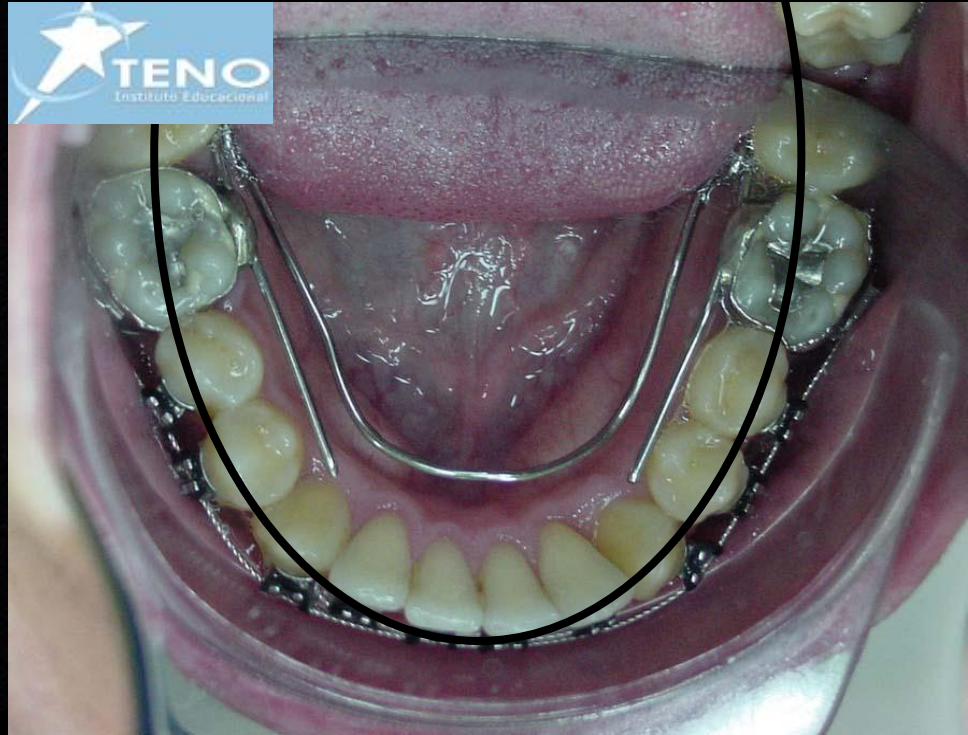
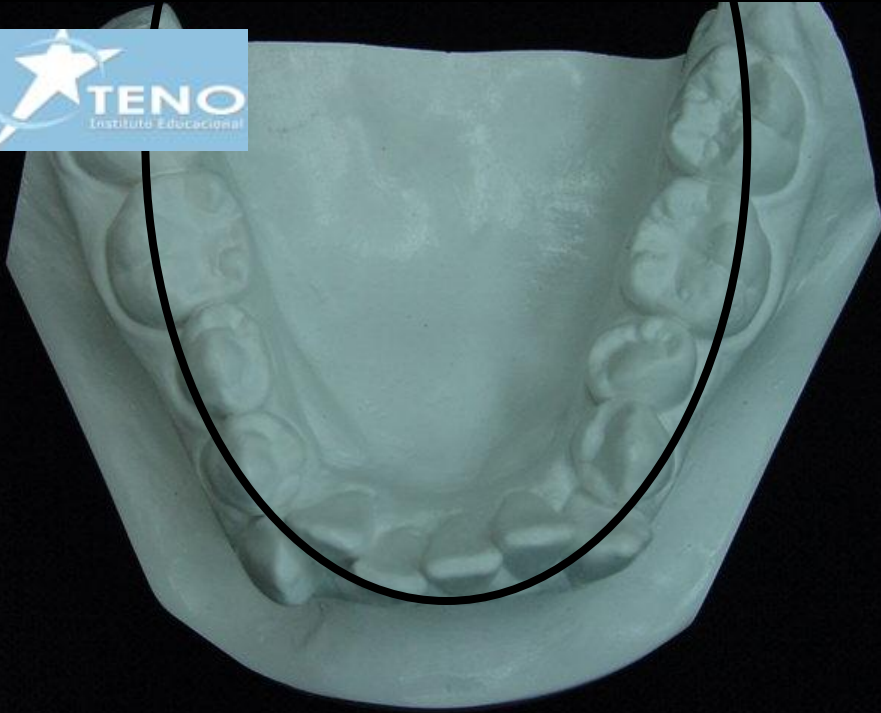


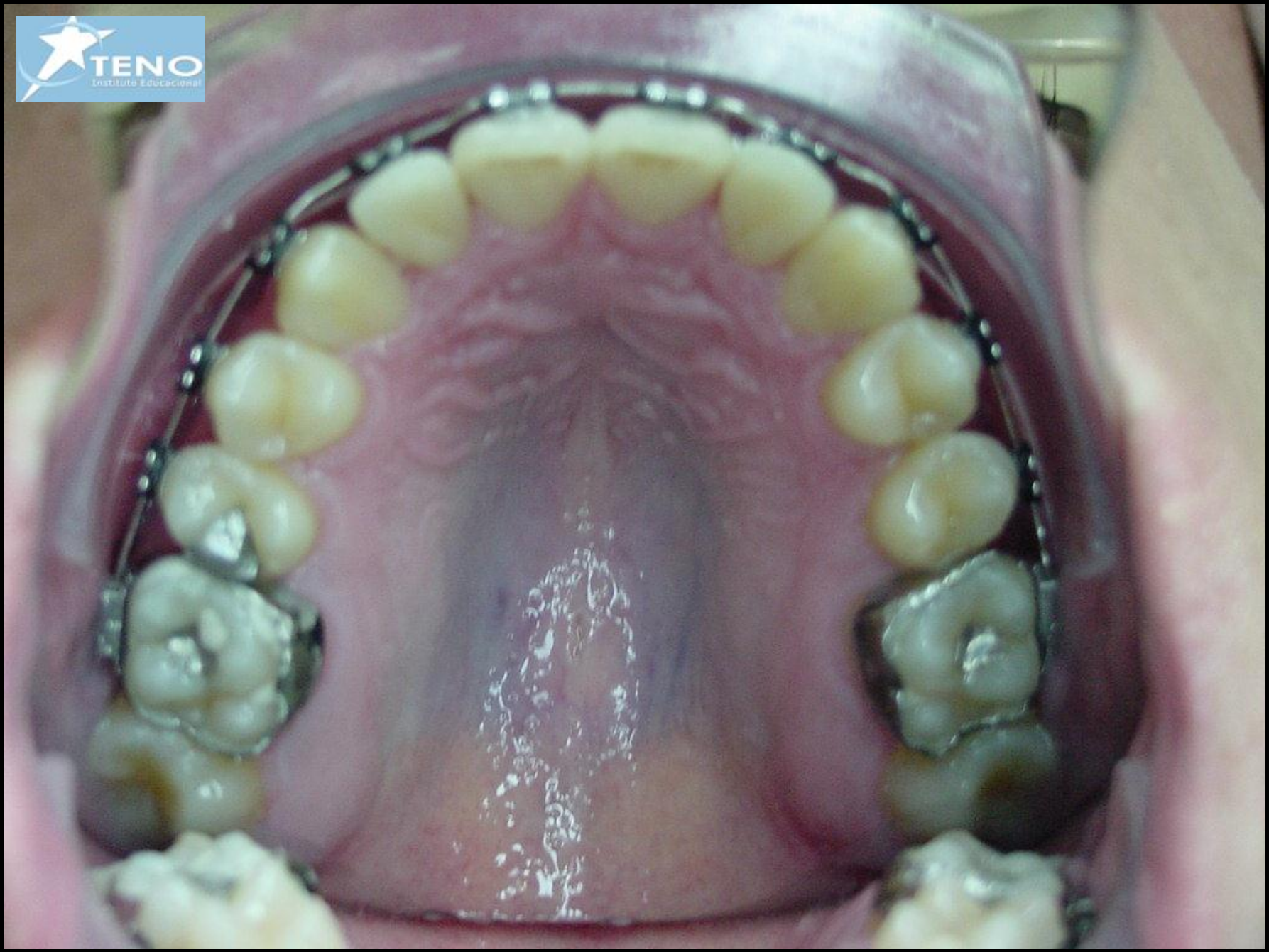







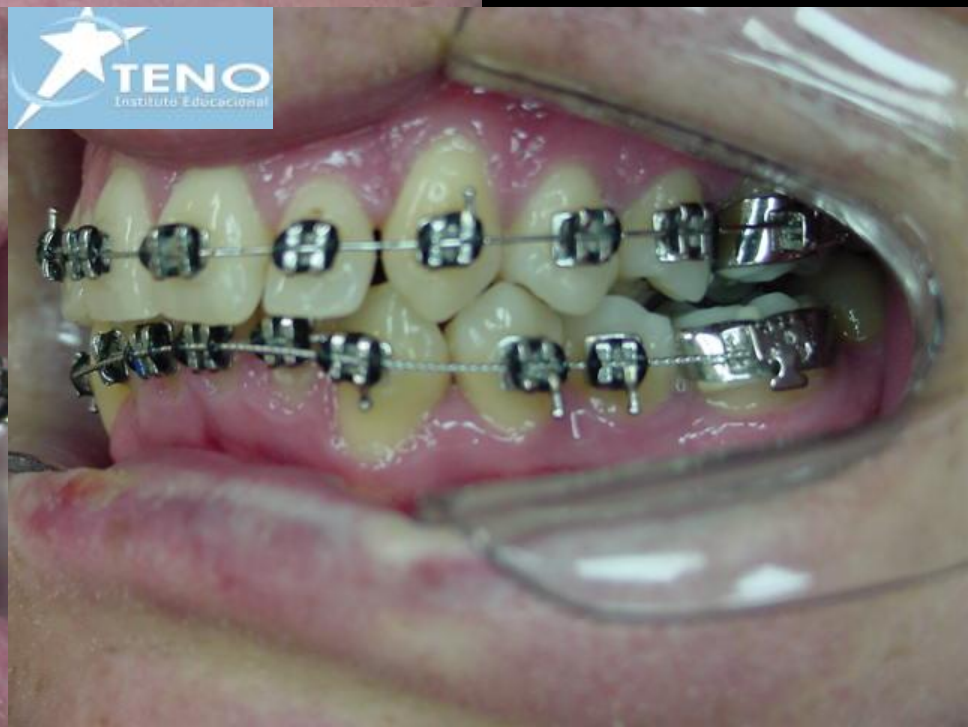
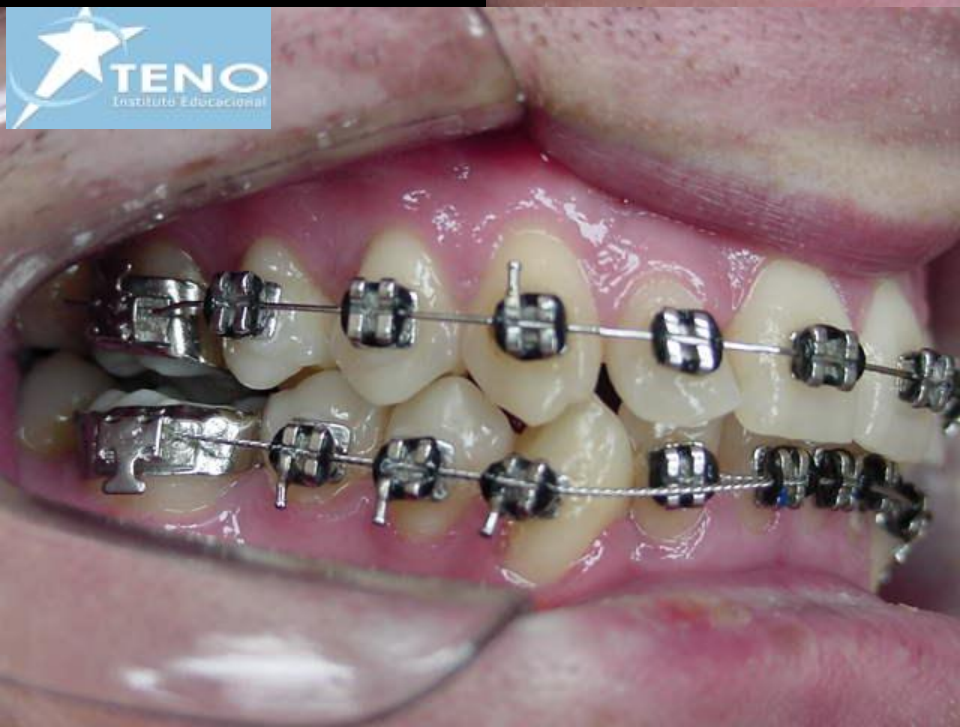
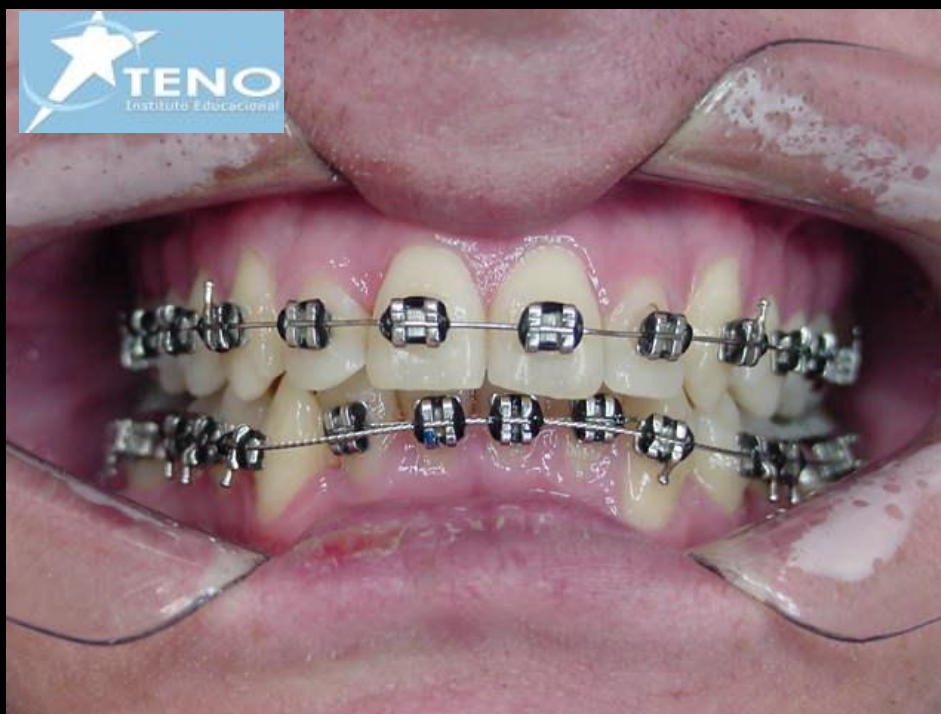


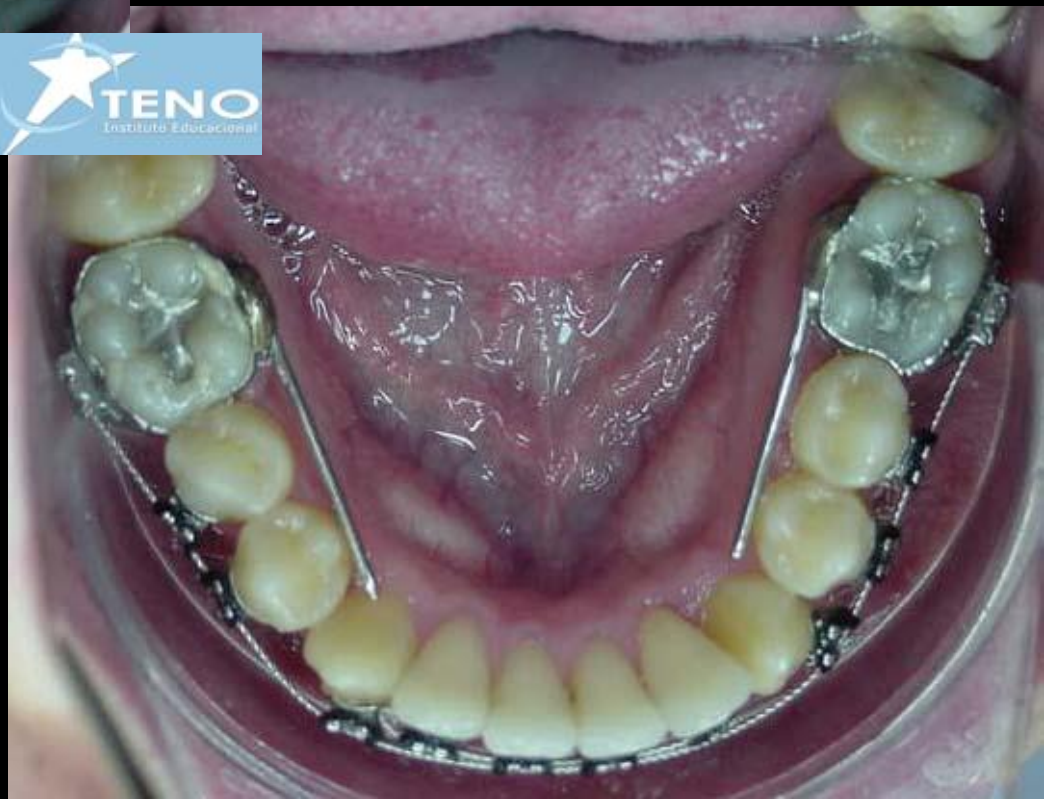
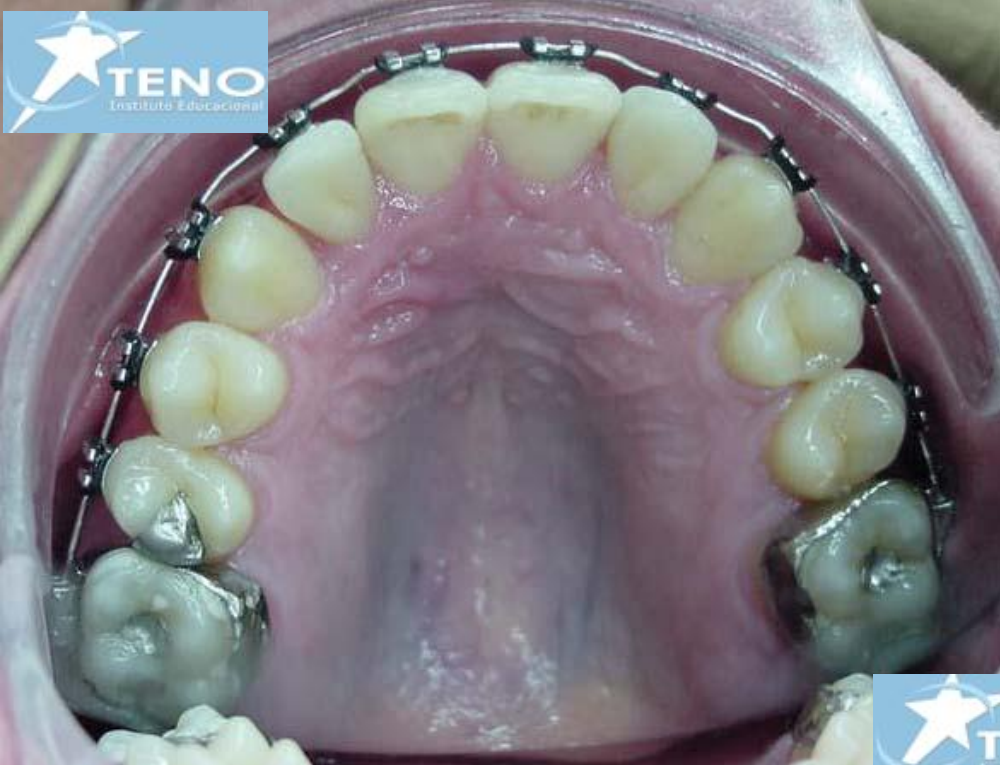
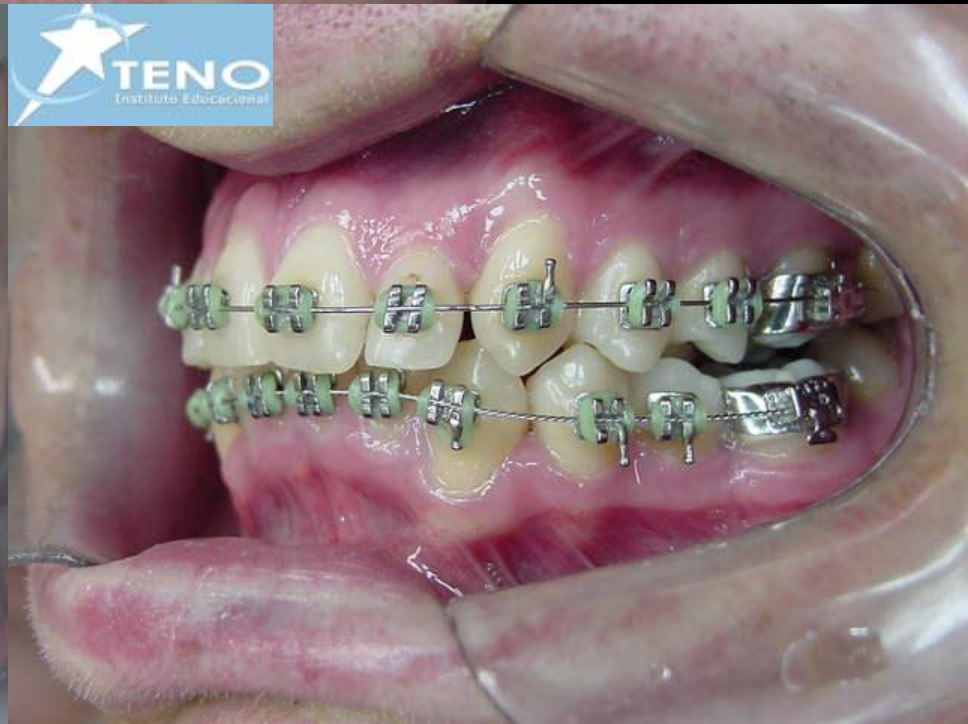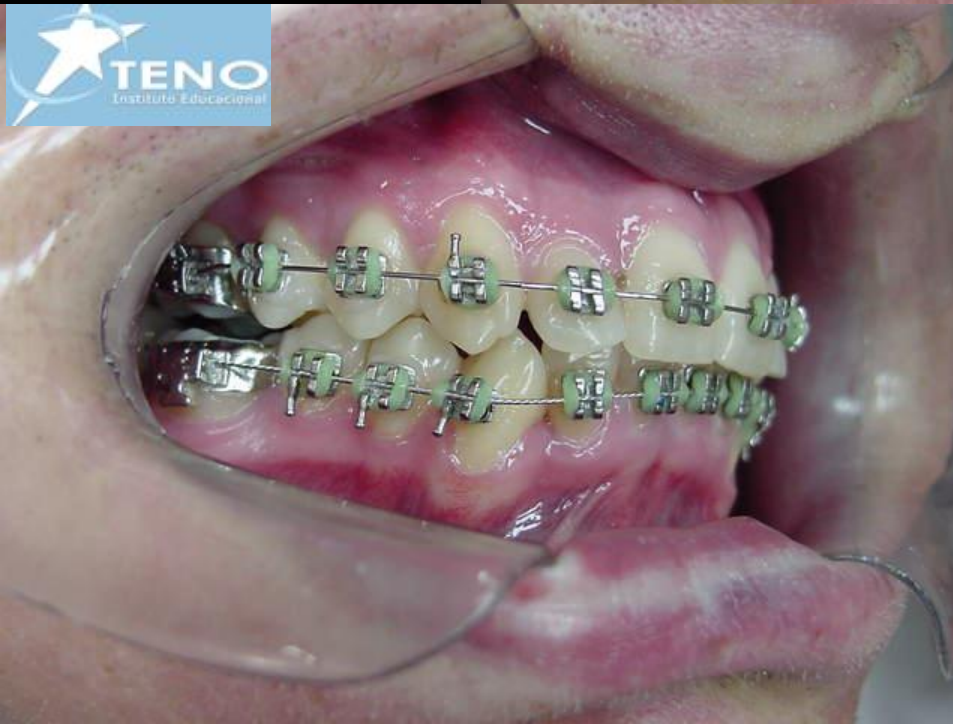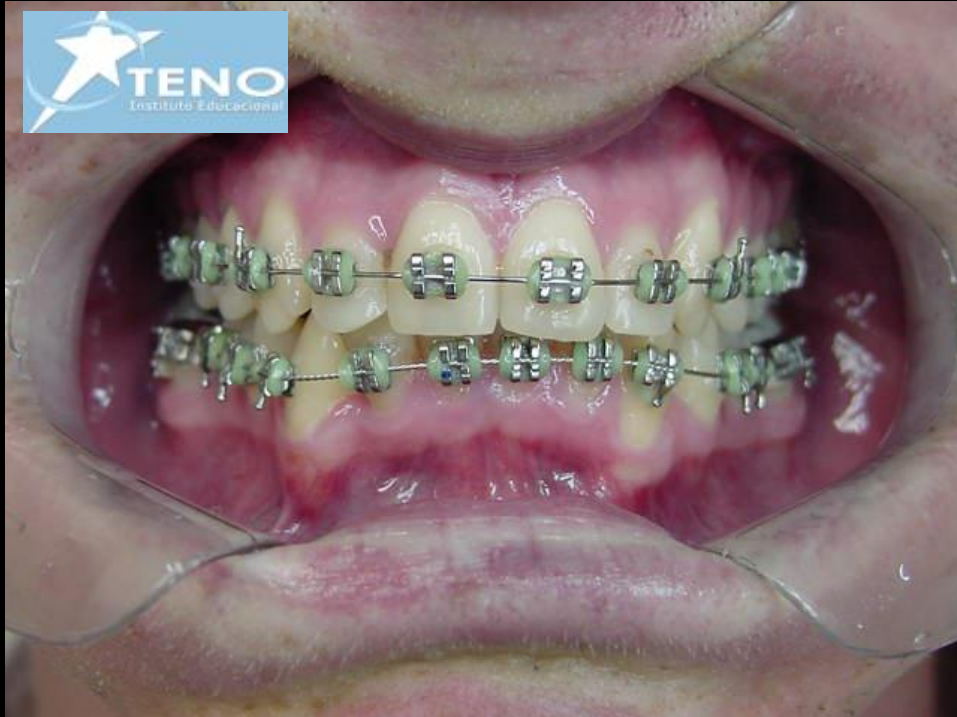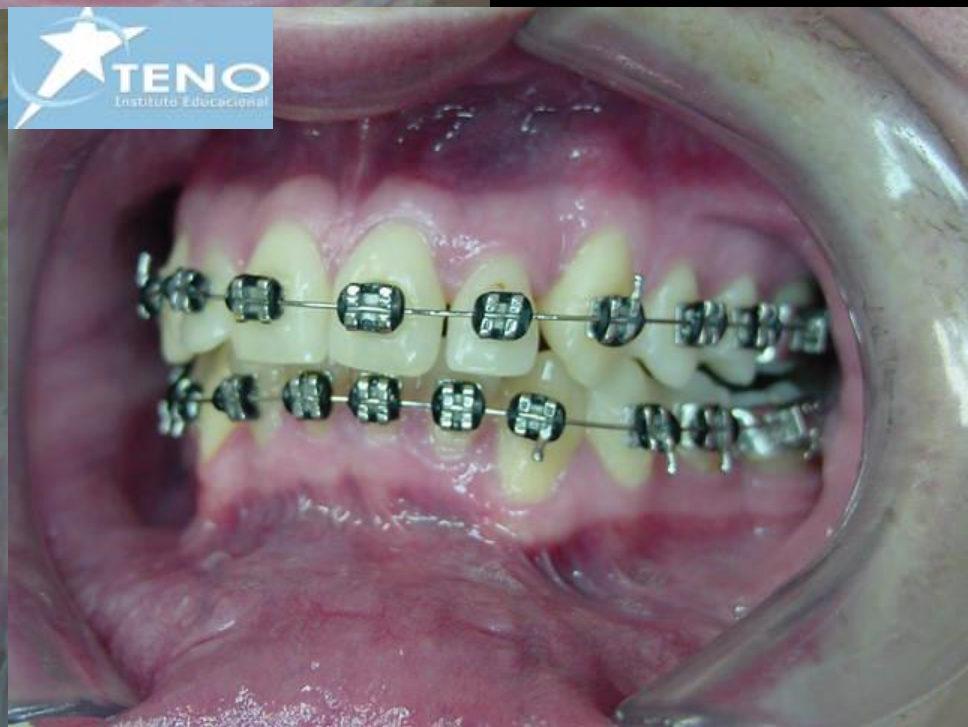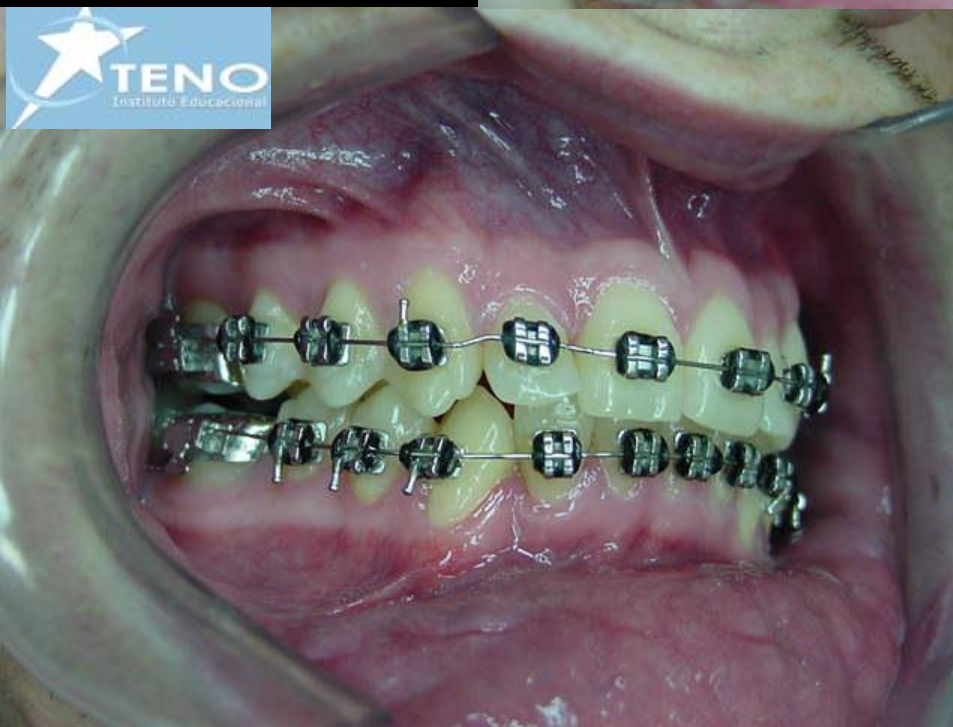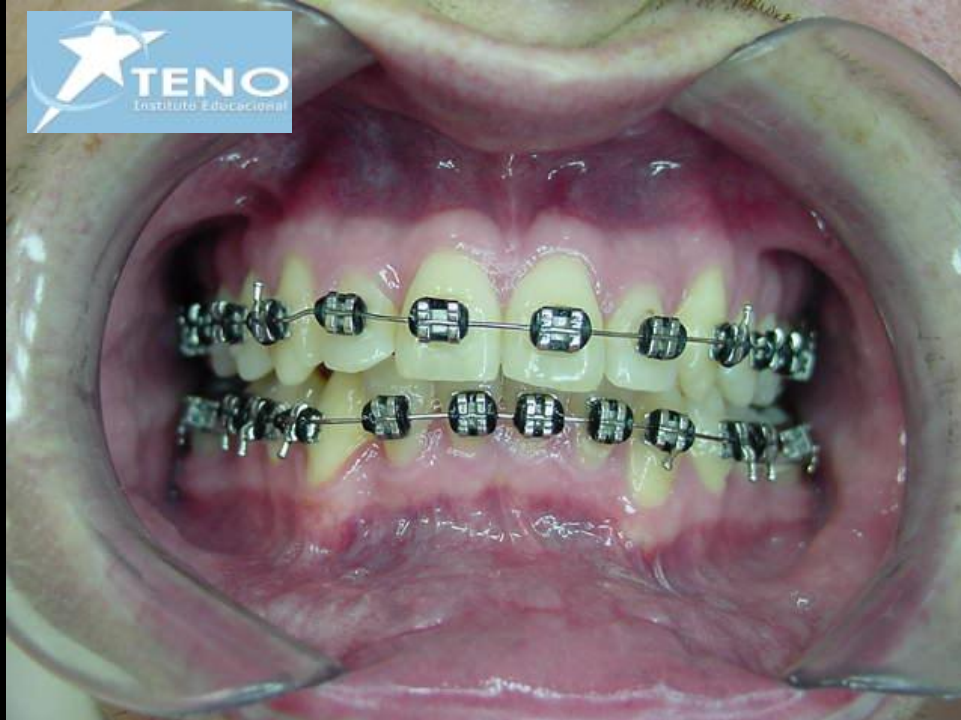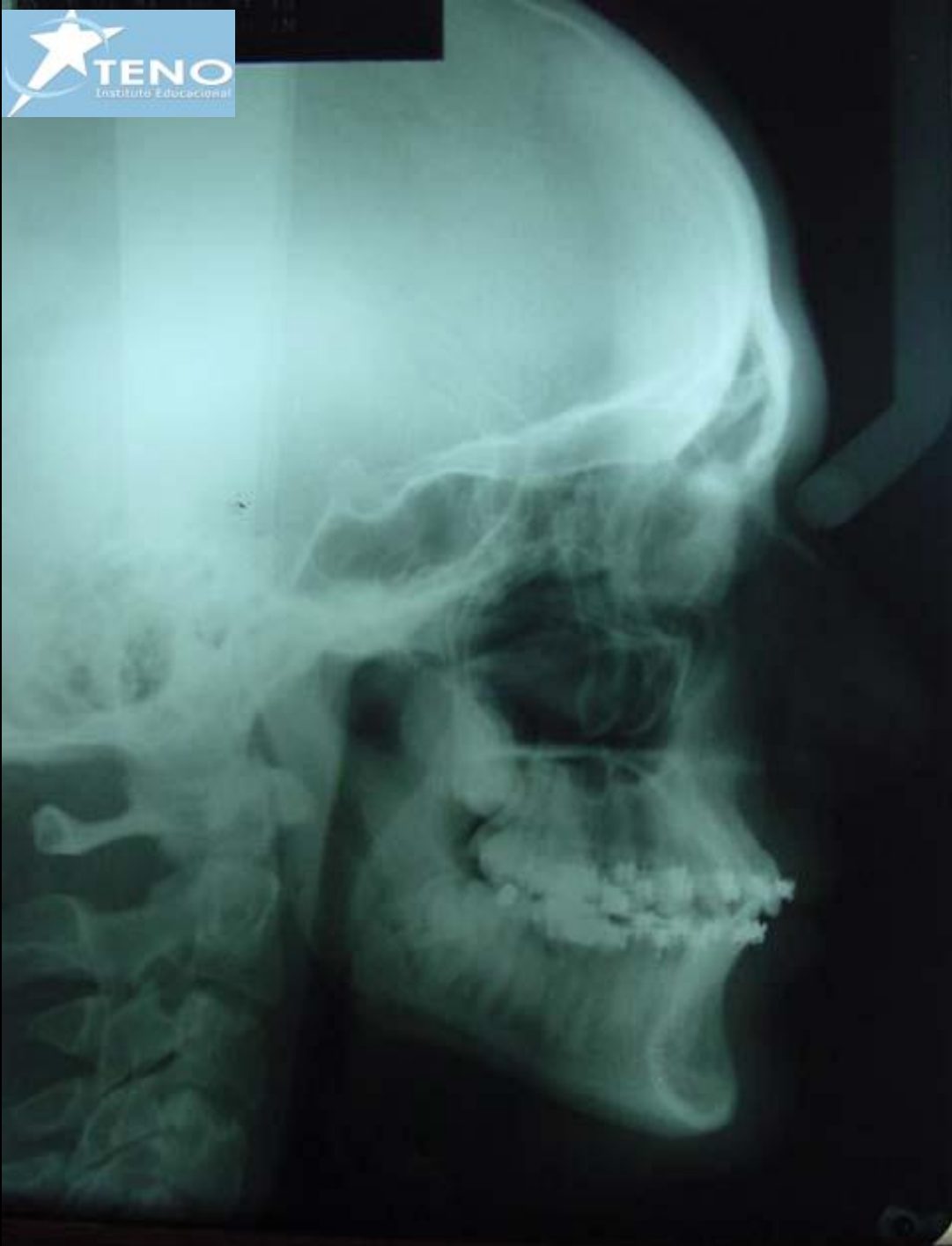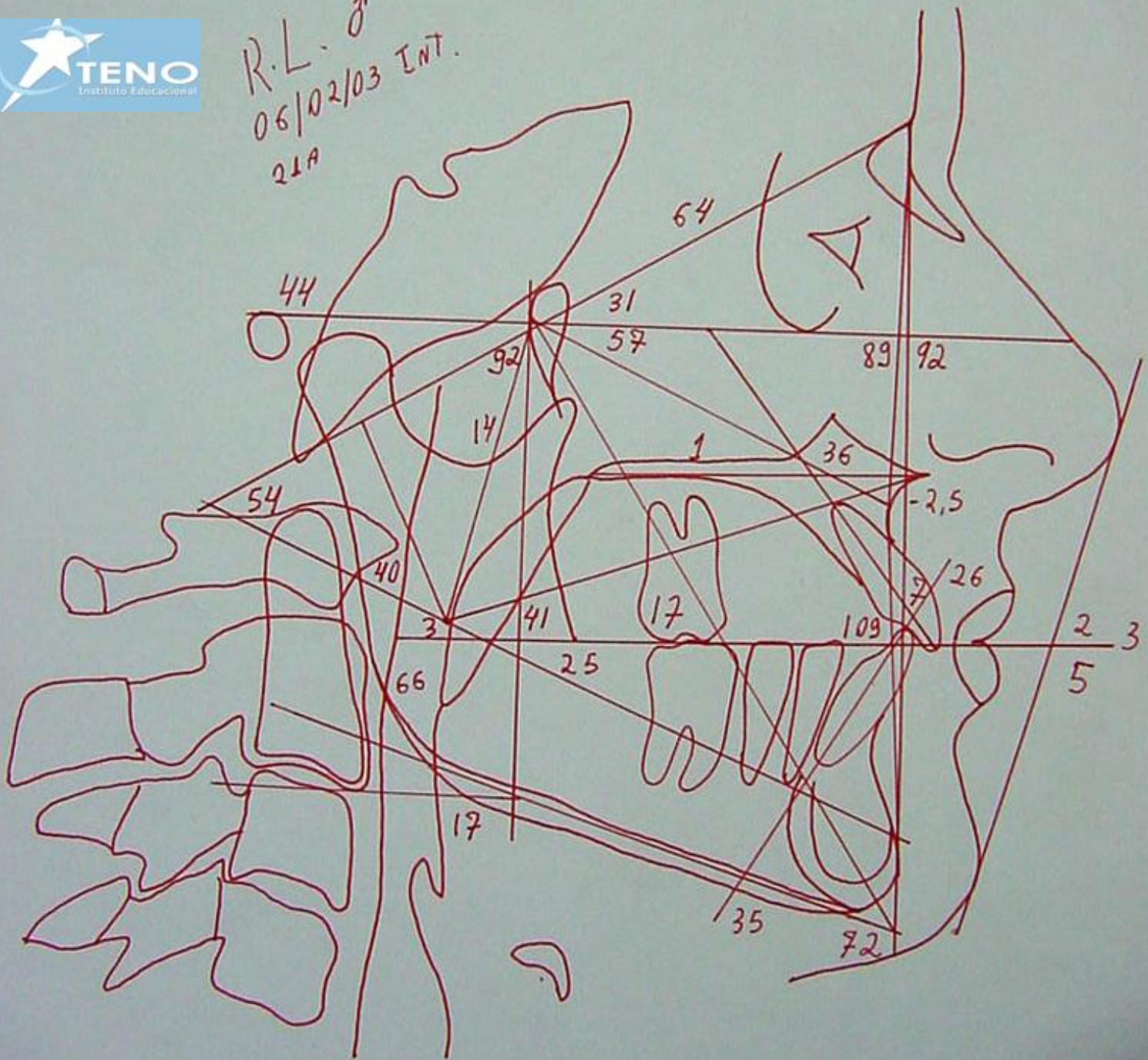




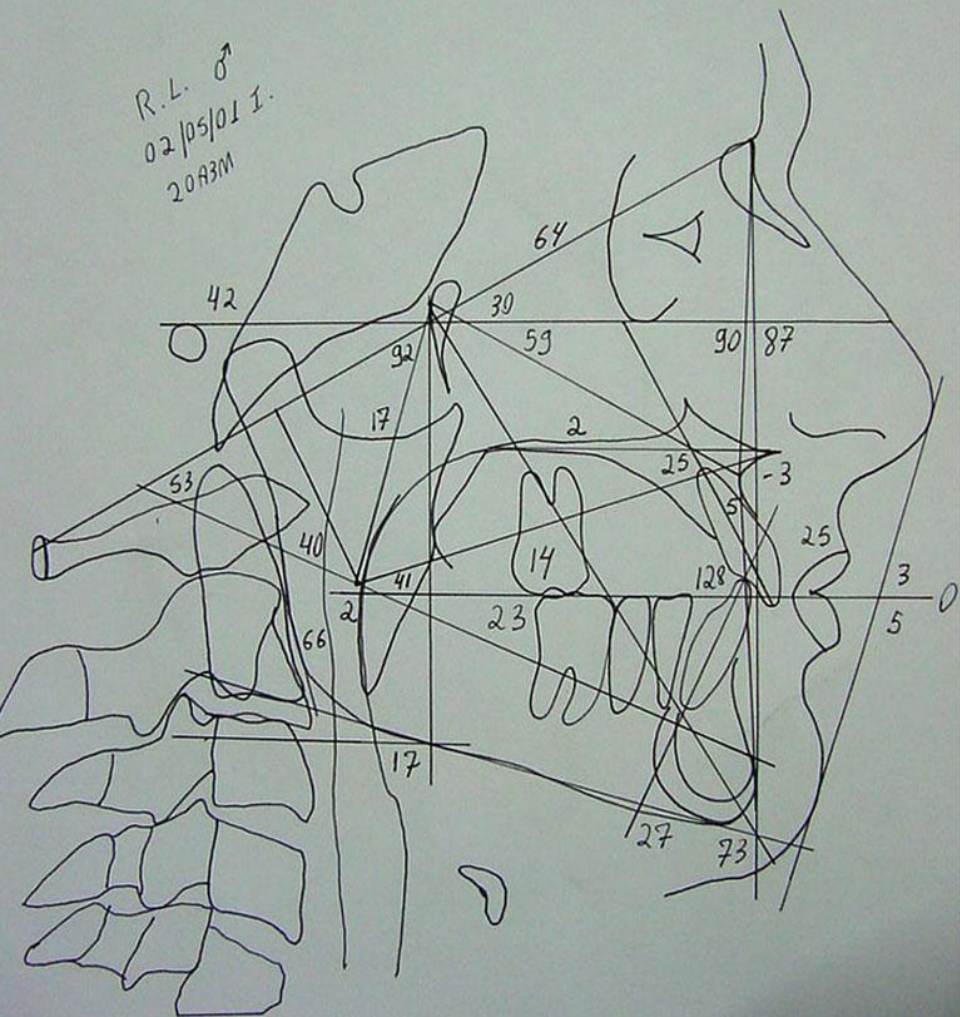




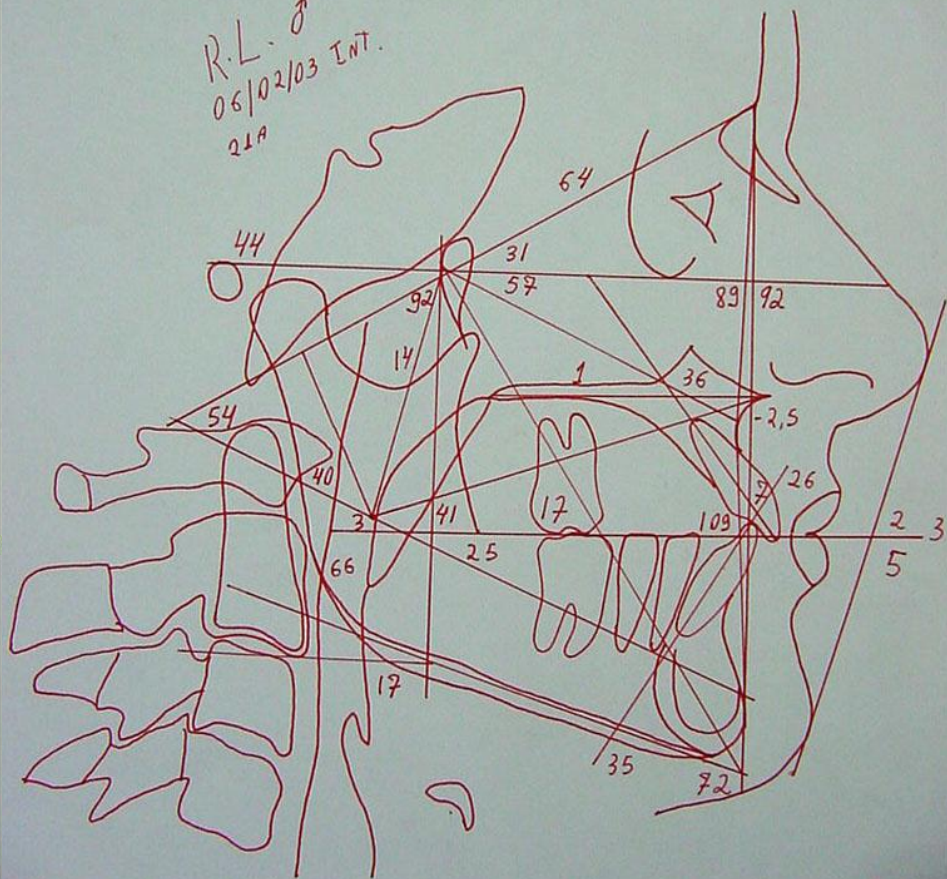
R.L. ♂  
06/02/03 INT.  
21A

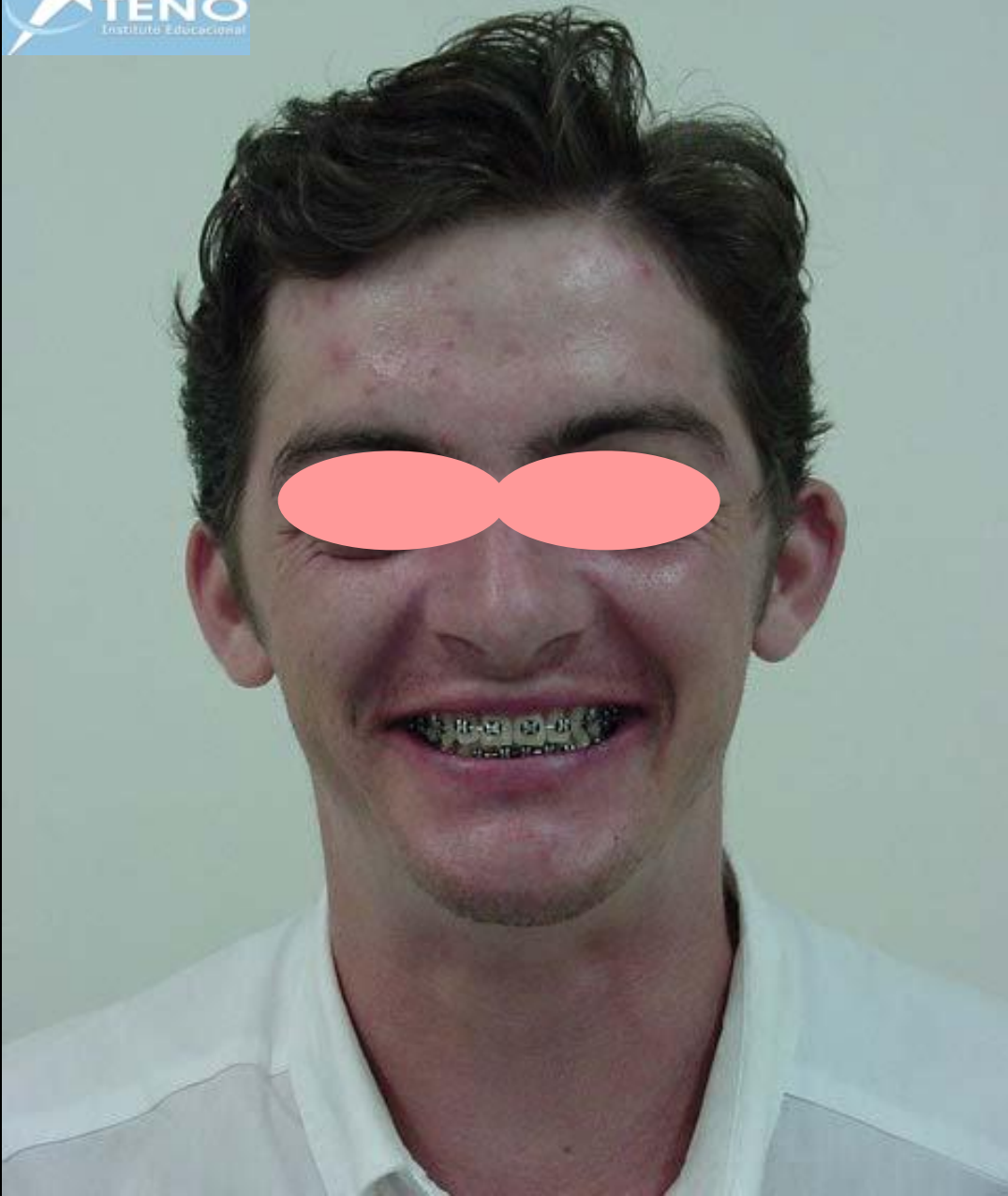

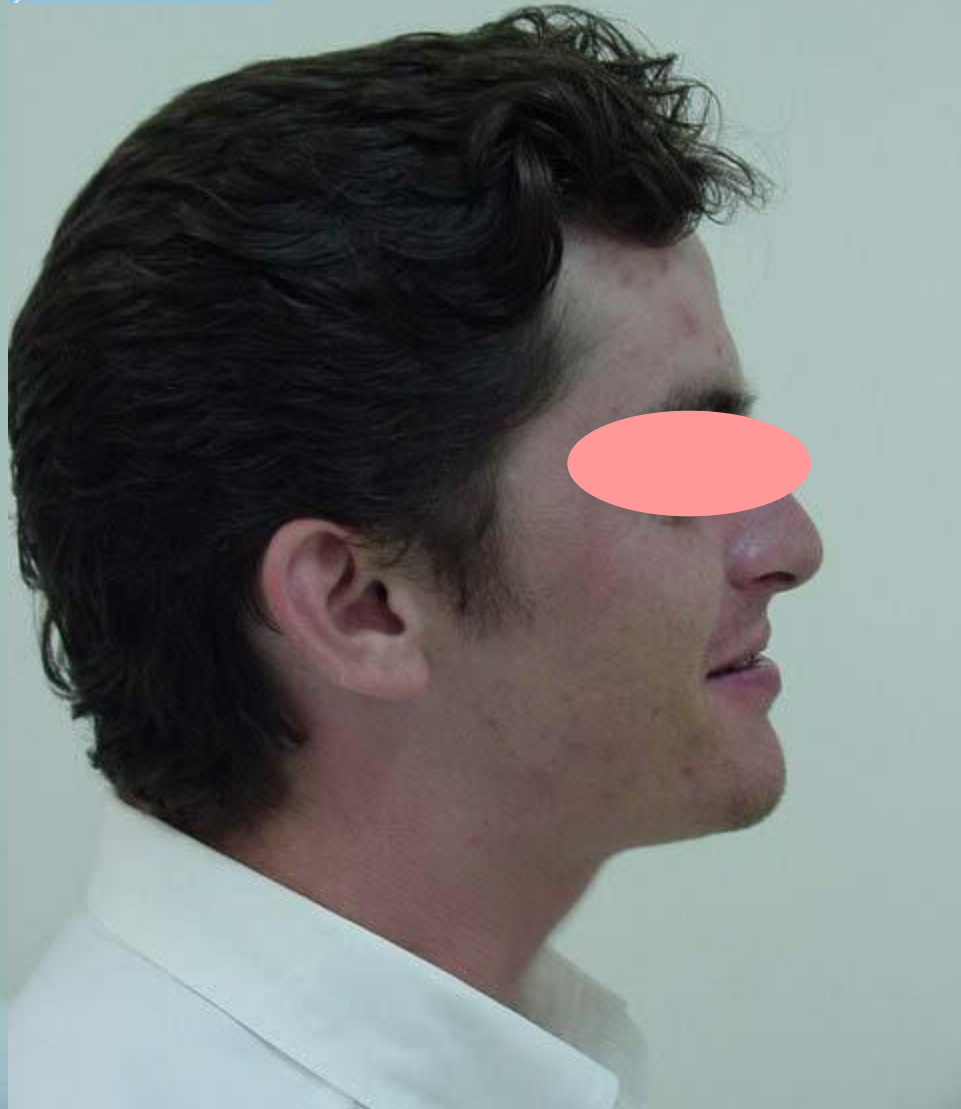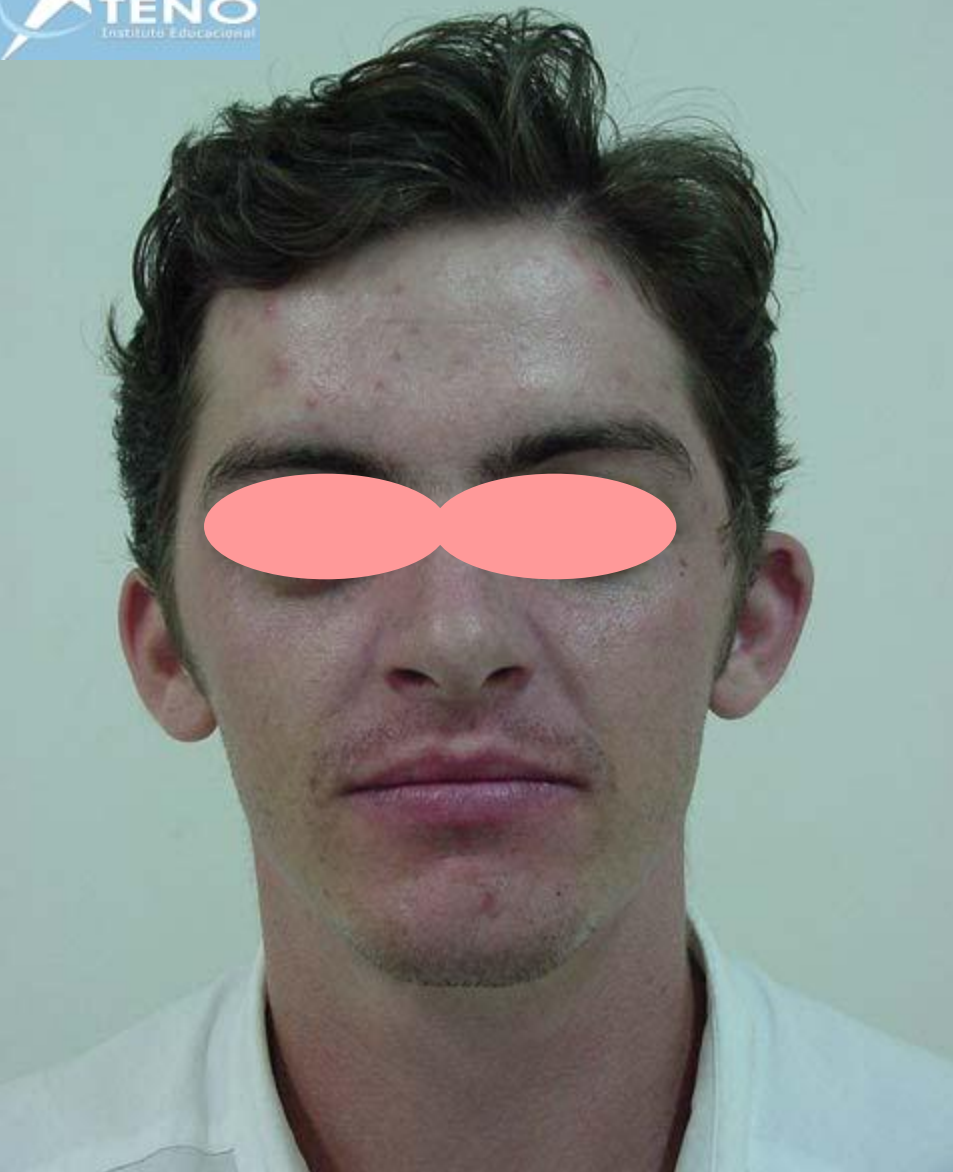R.L. ♂  
02/05/01 I.  
20A3M

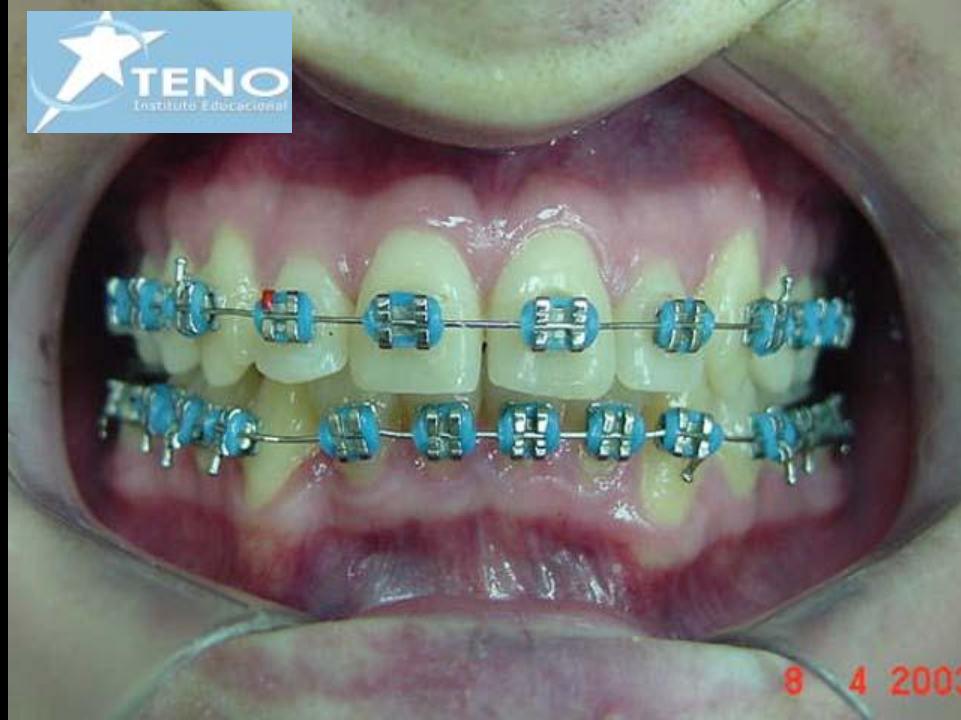

R.L. ♂  
06/02/03 INT.  
21A

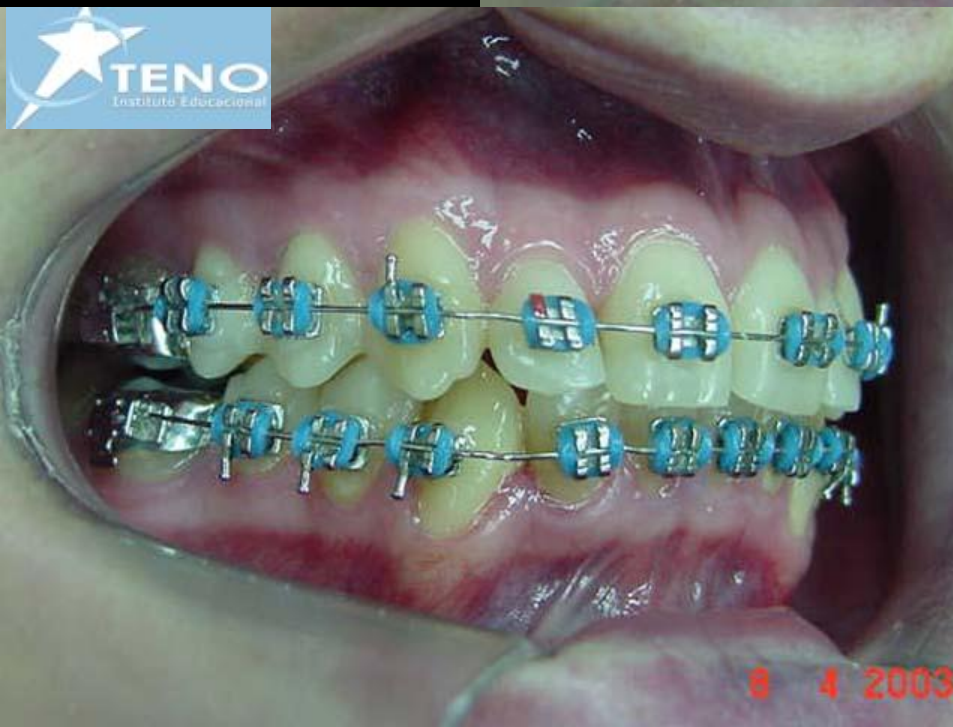




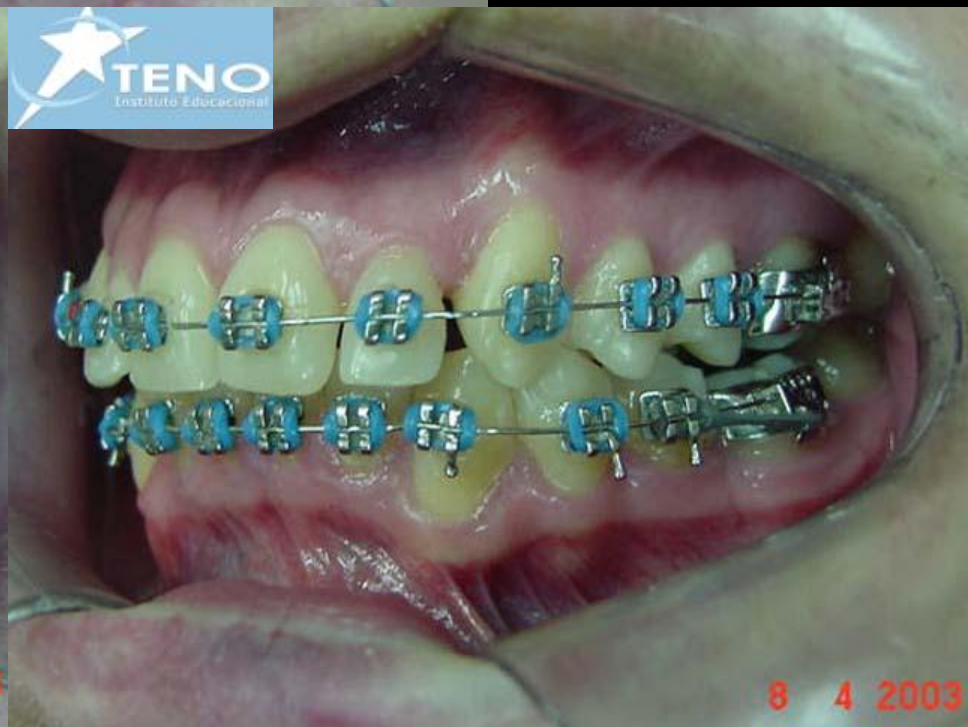


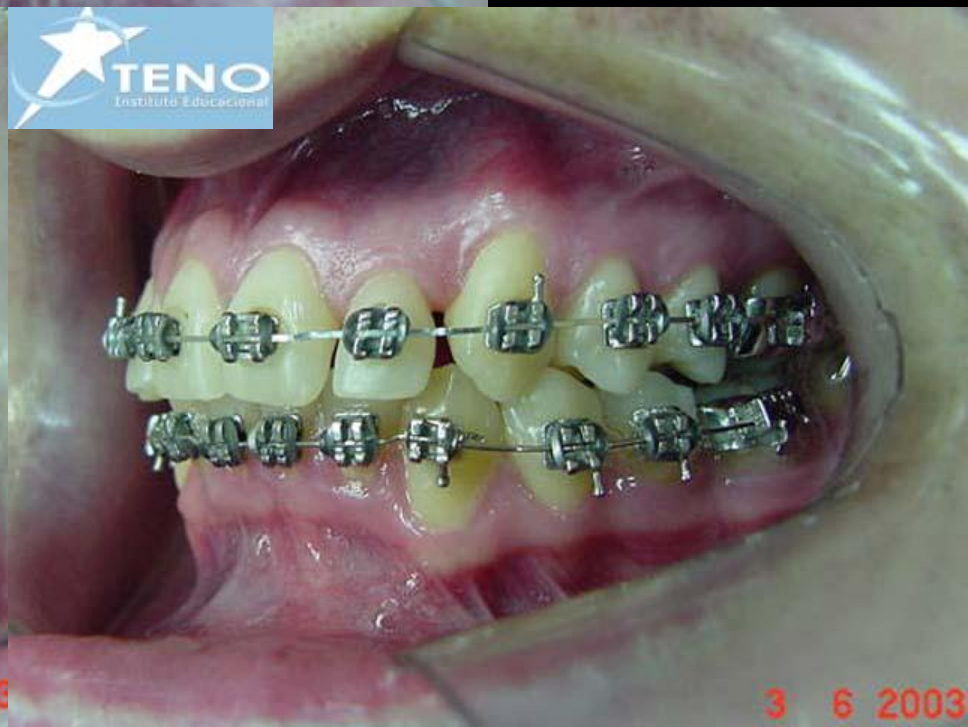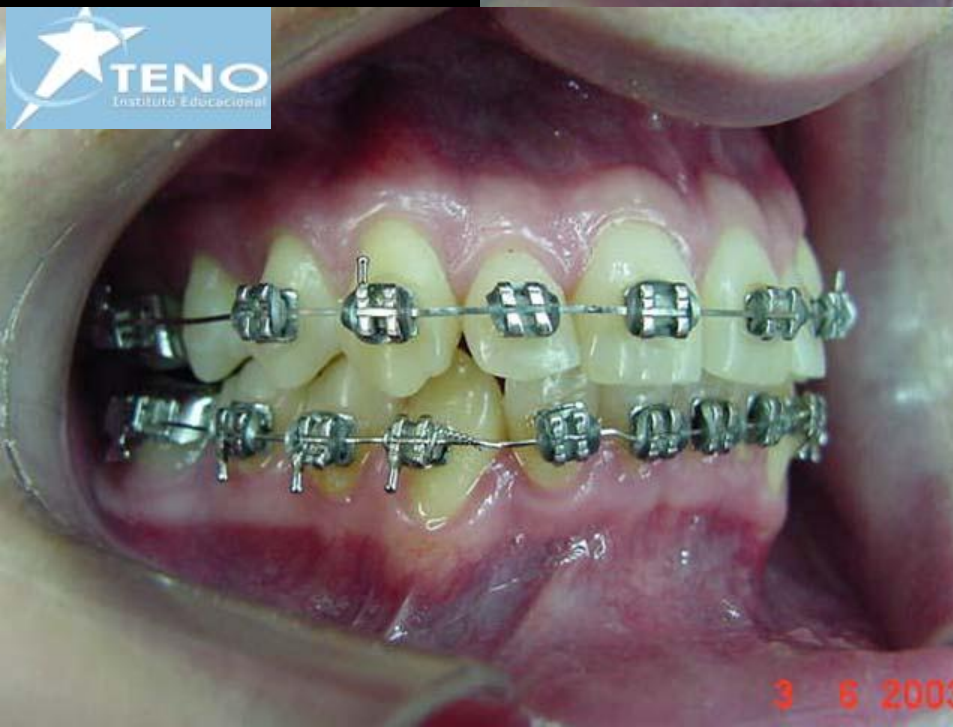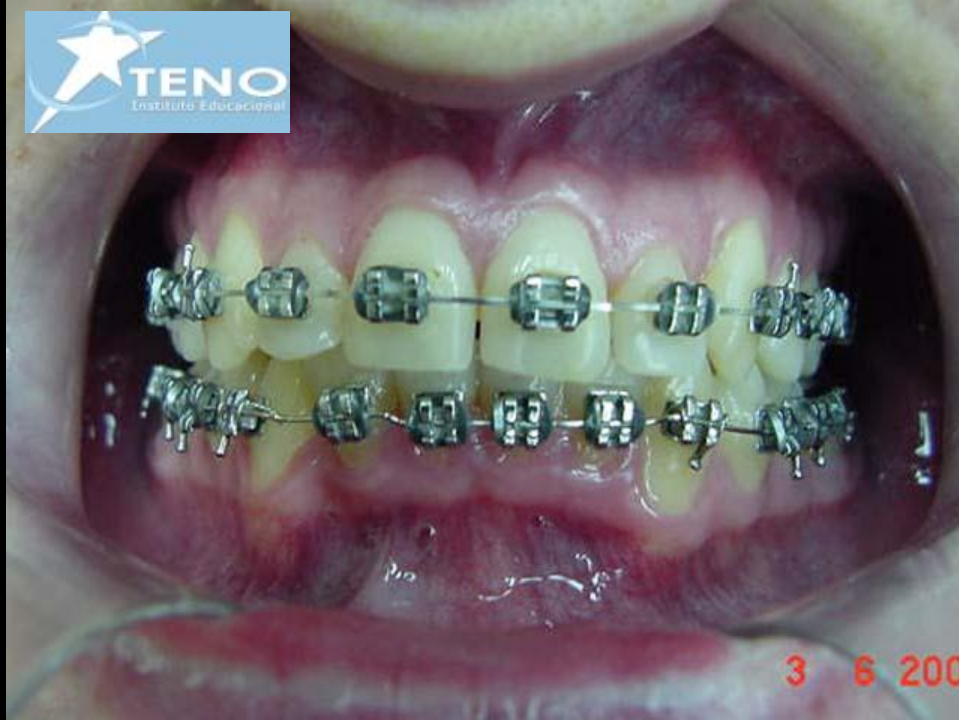8 4 2003

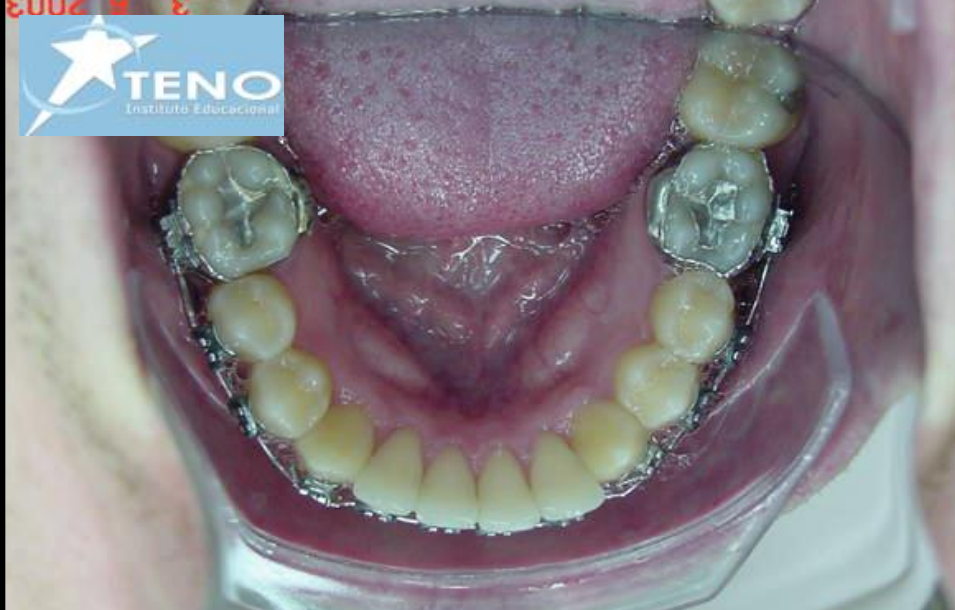
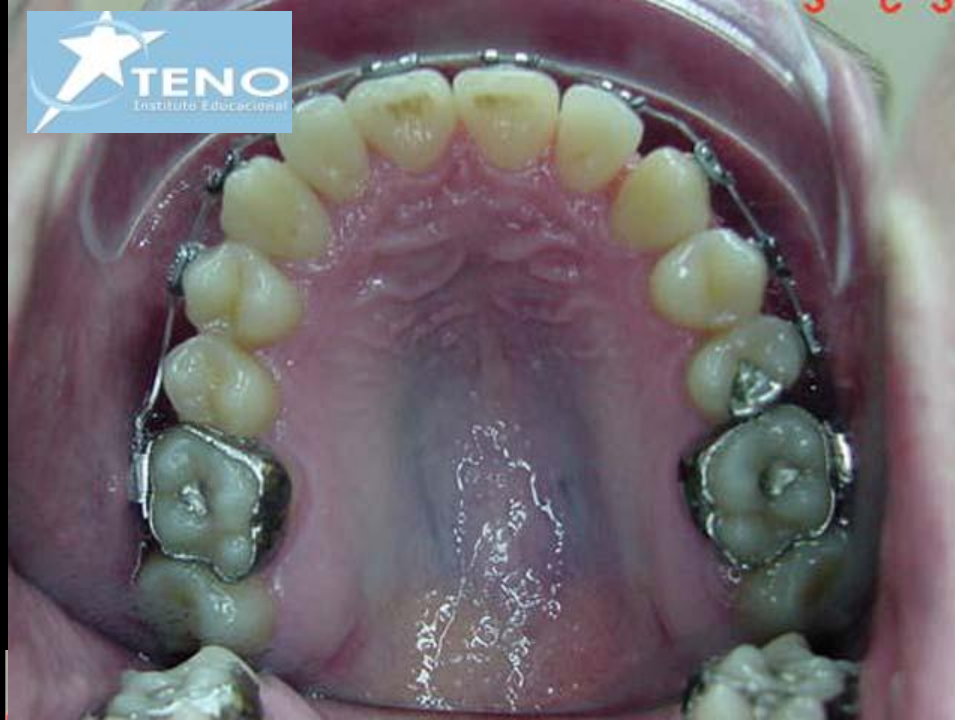
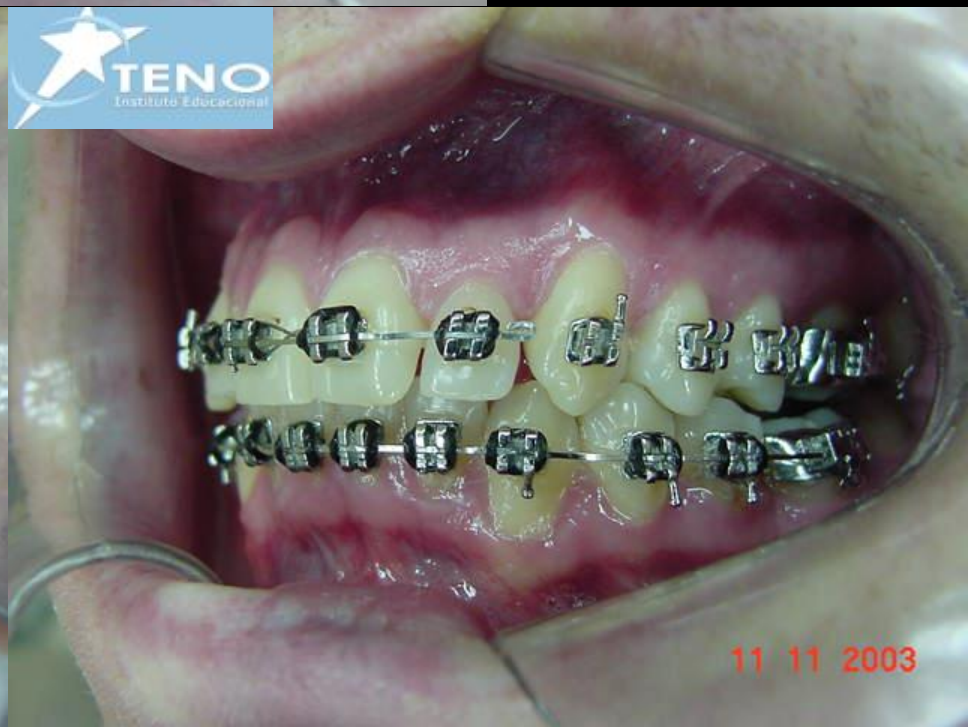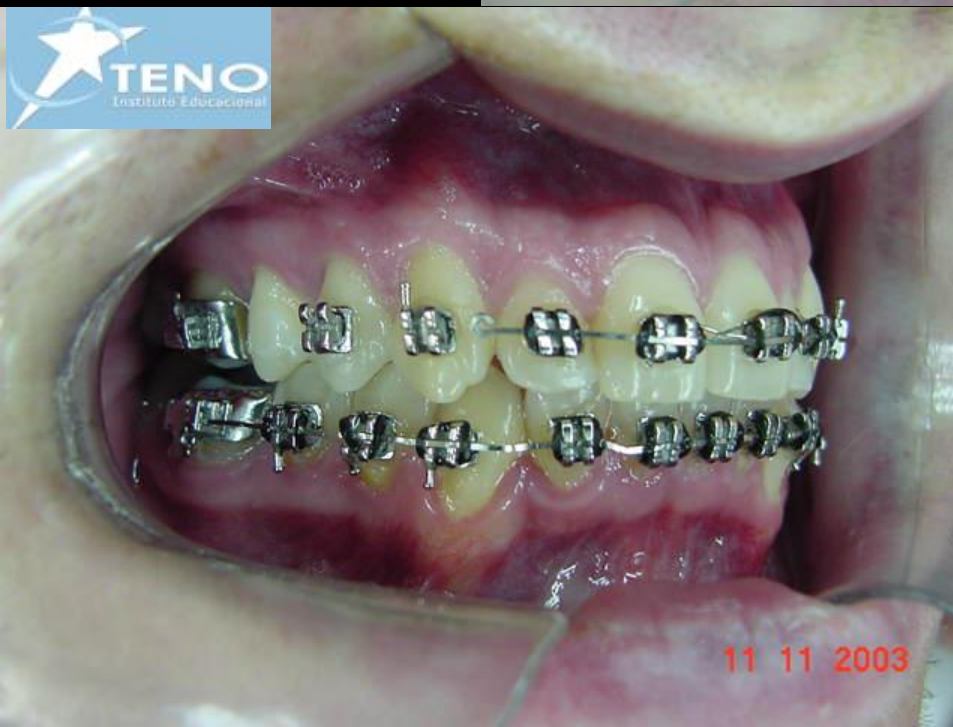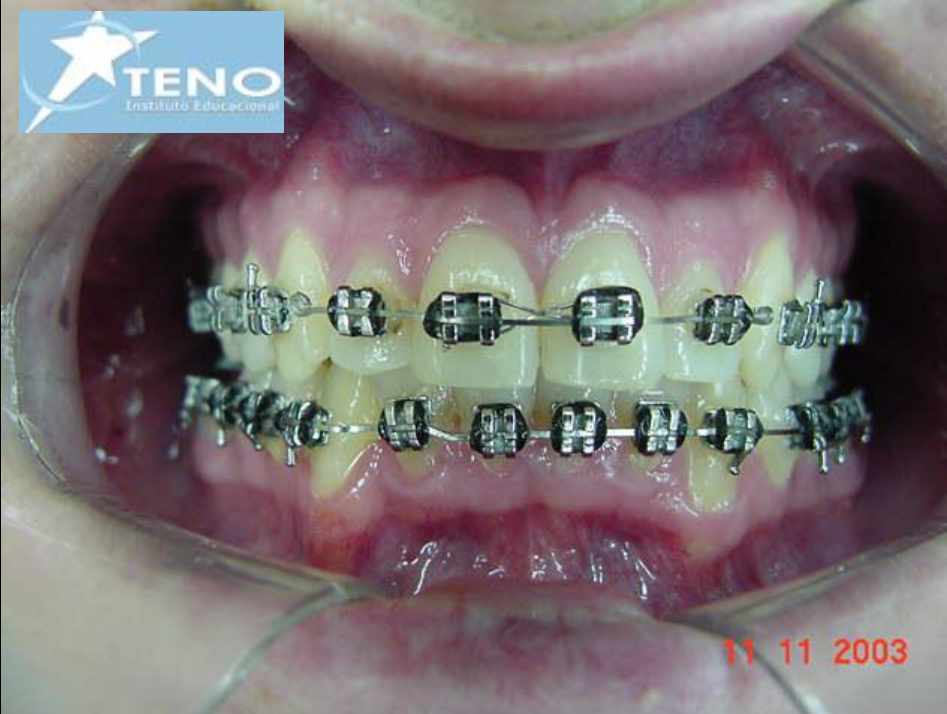8 4 2003

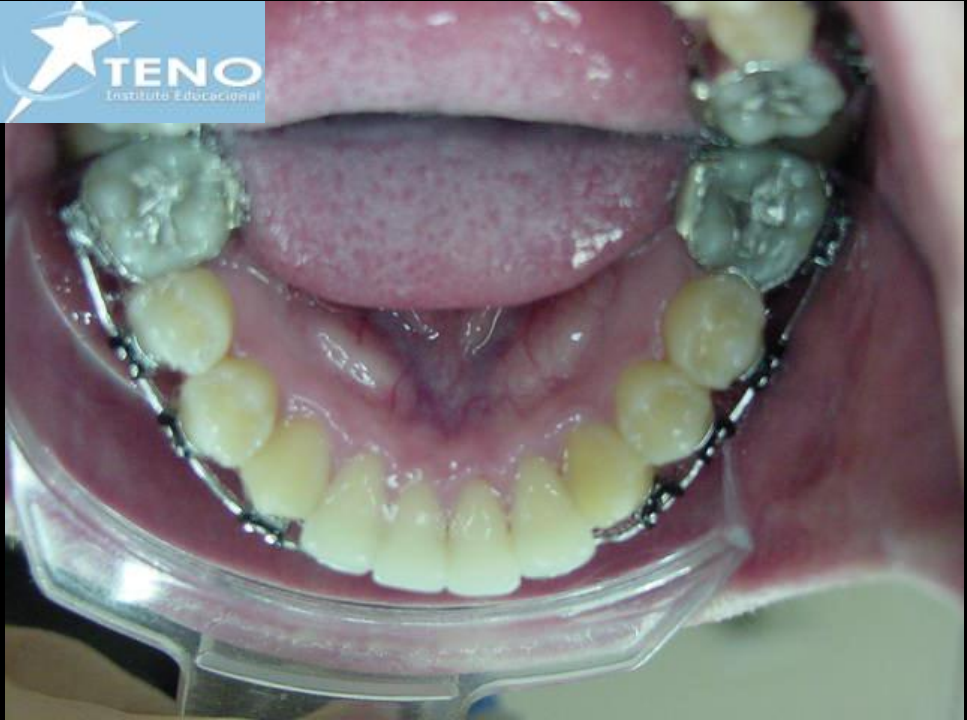
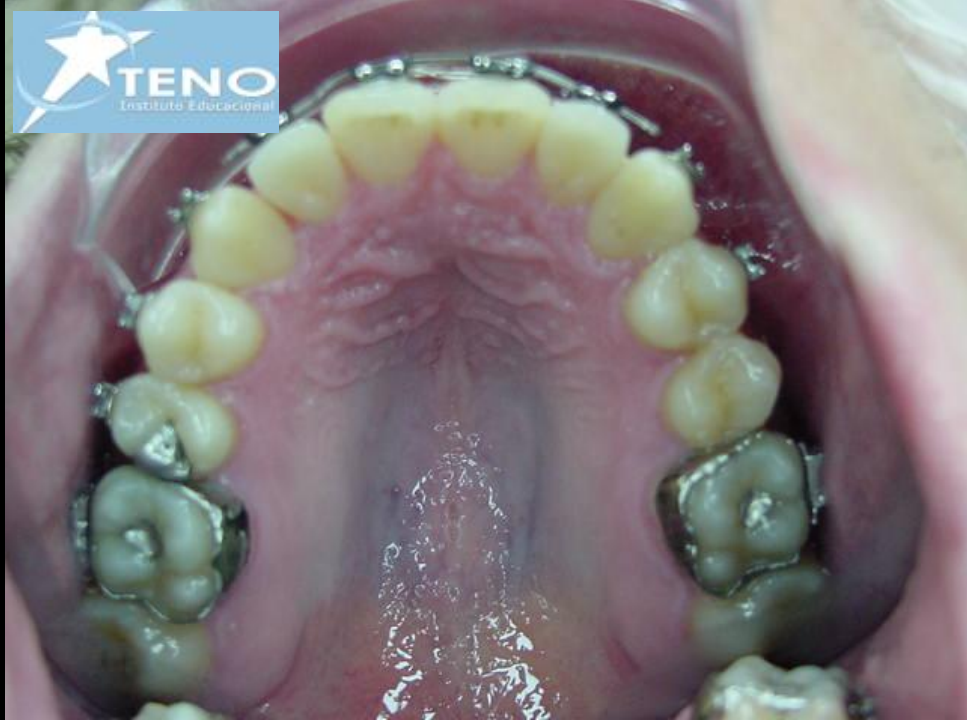
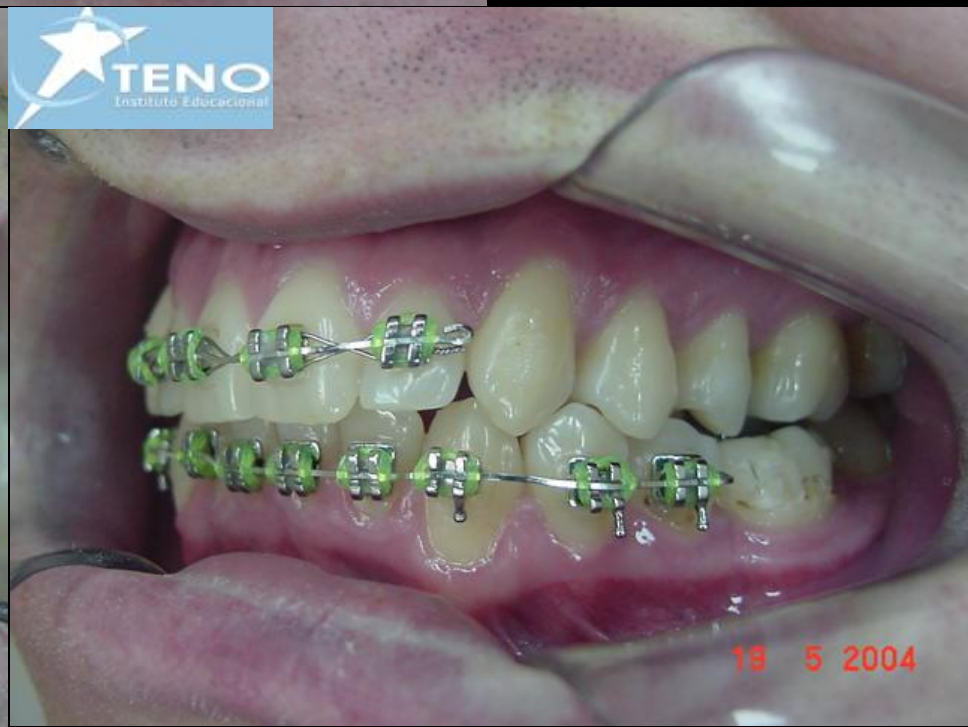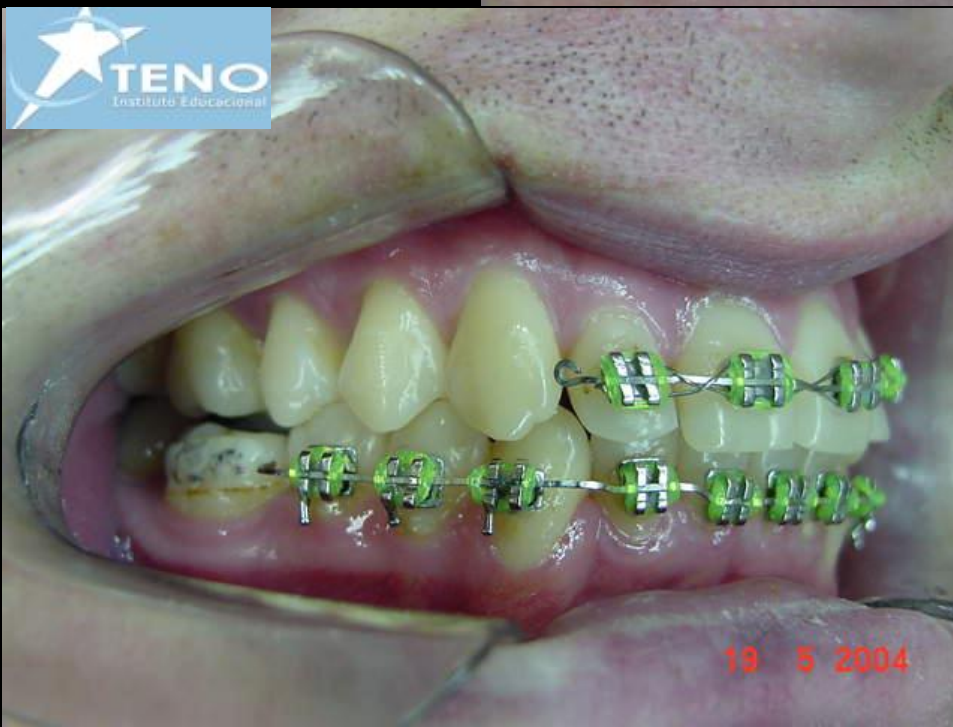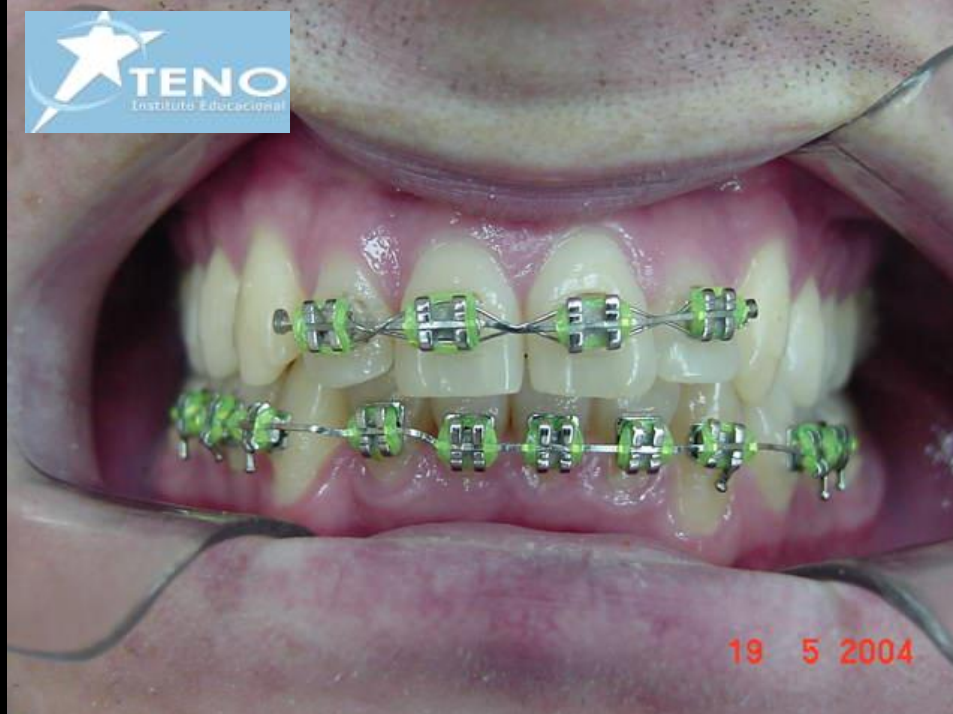8 4 2003

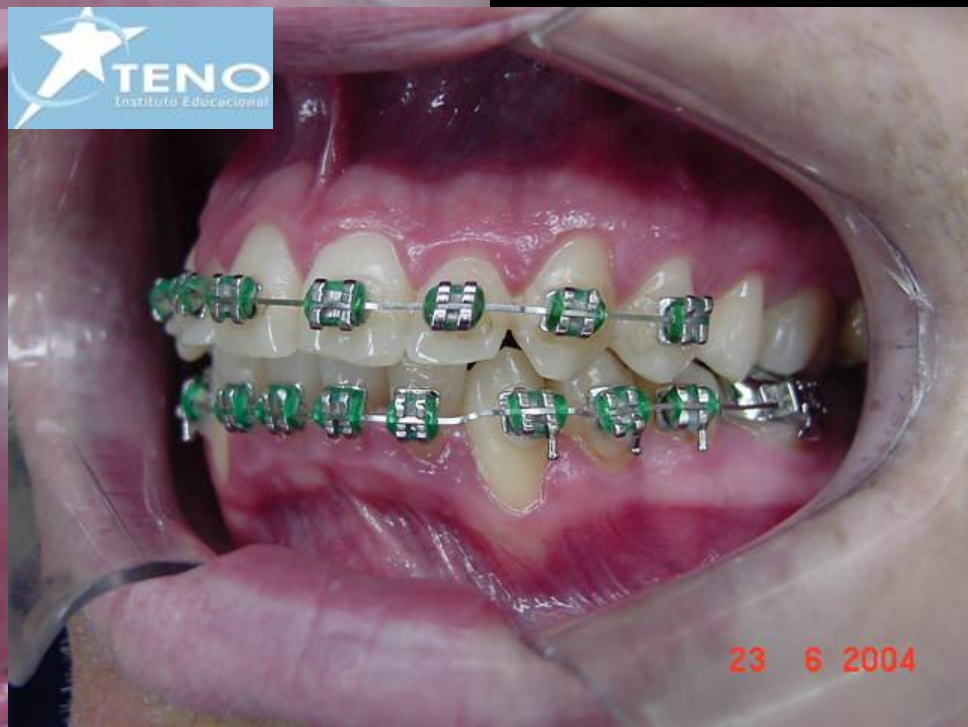
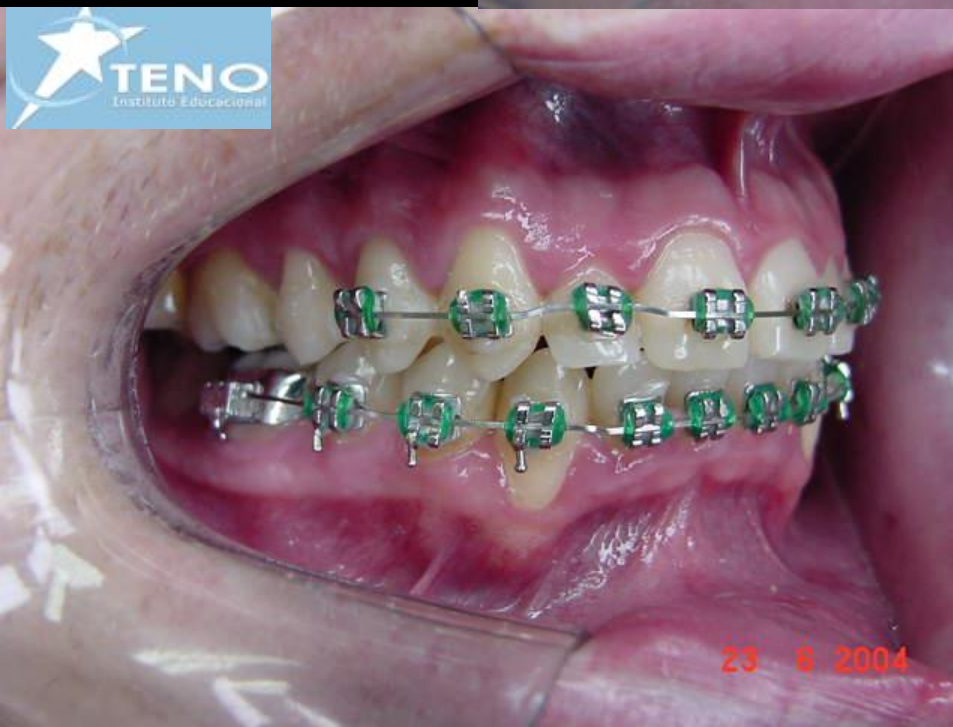
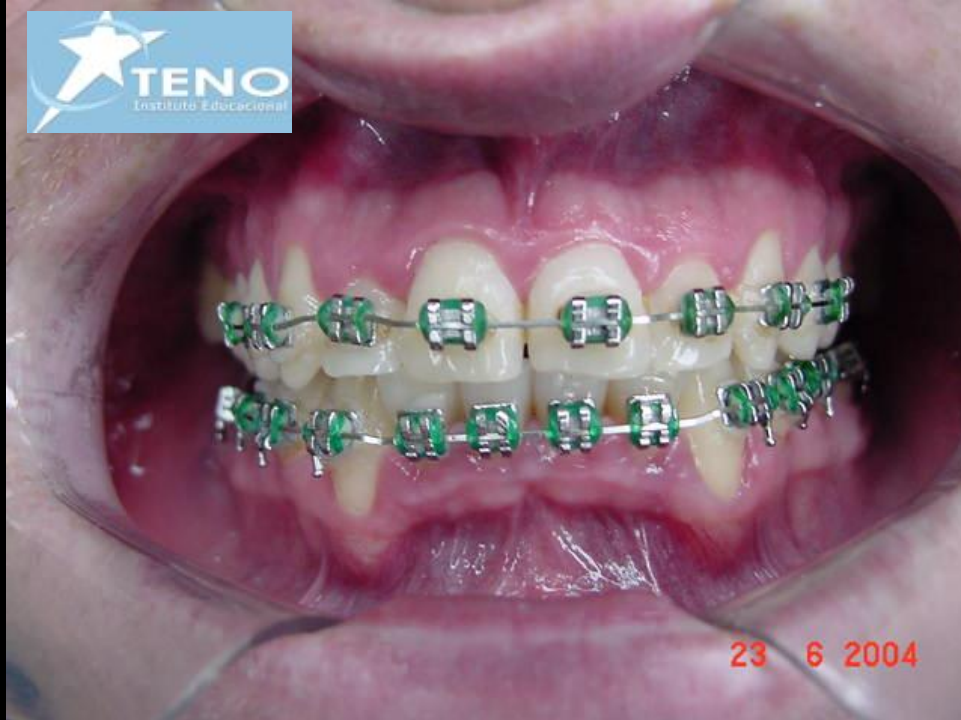


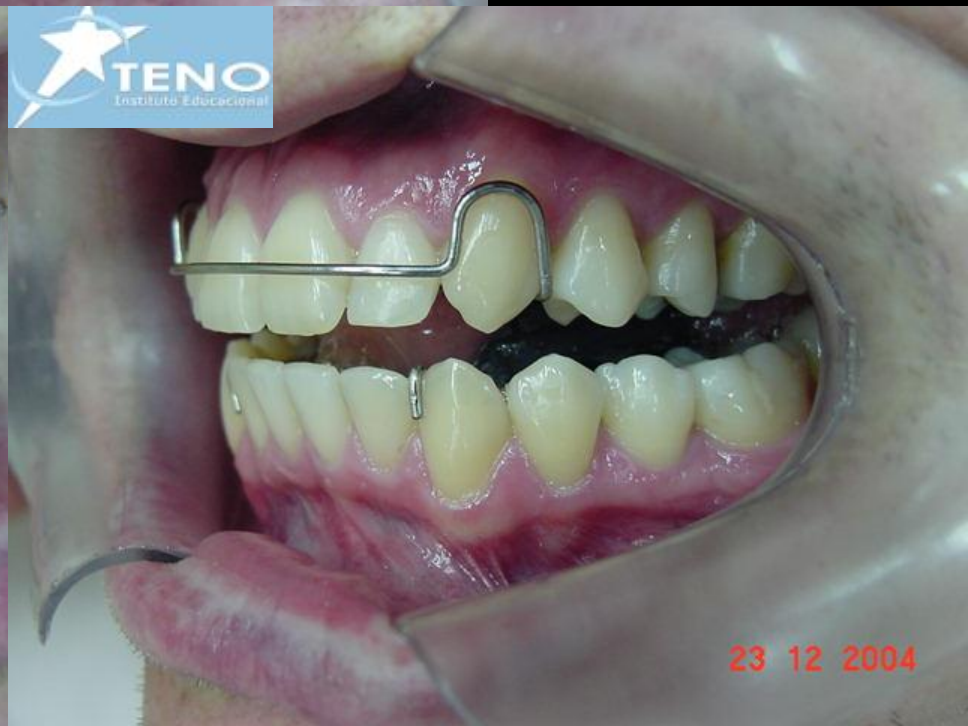
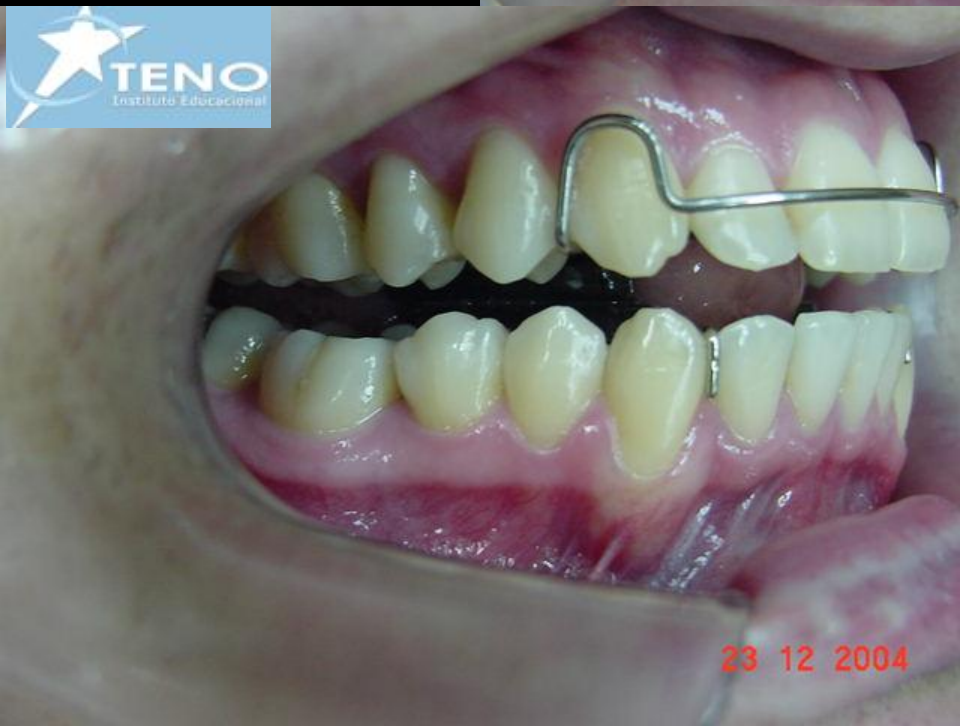
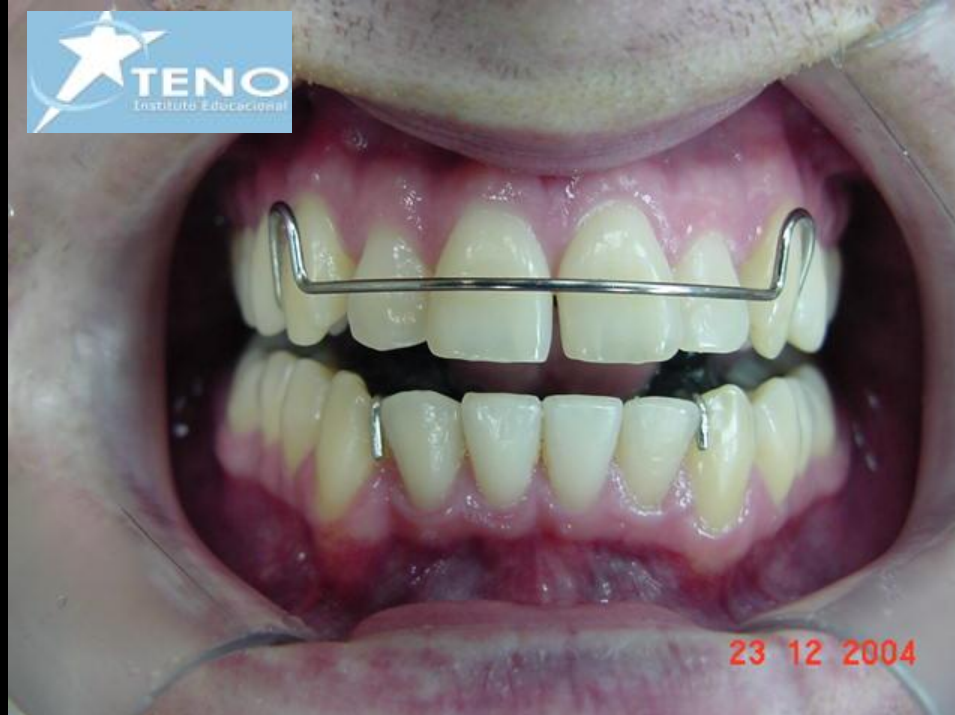


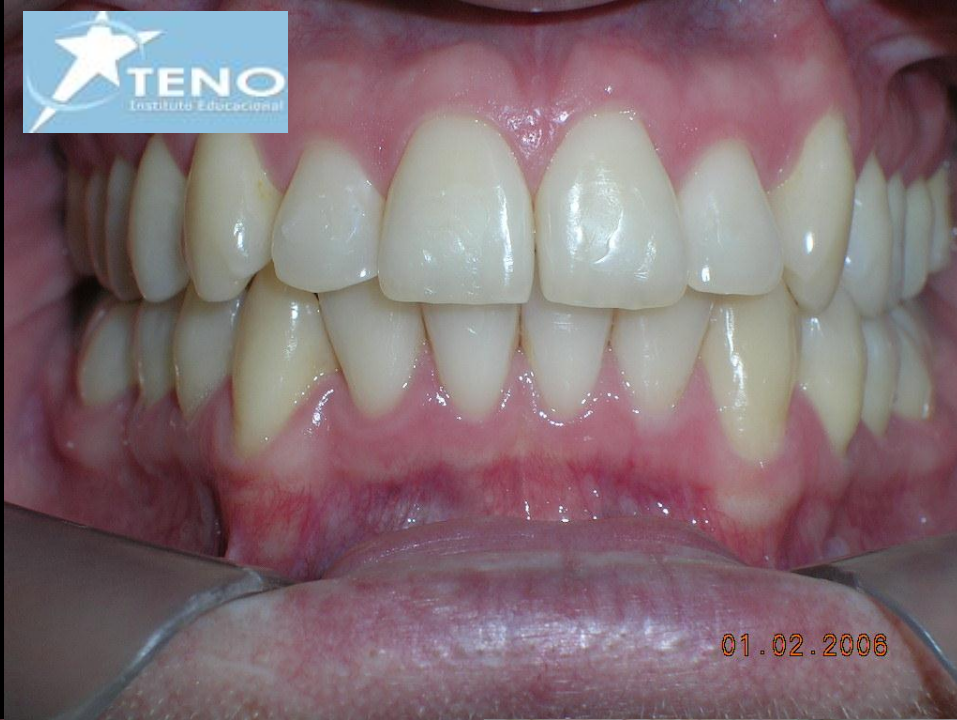




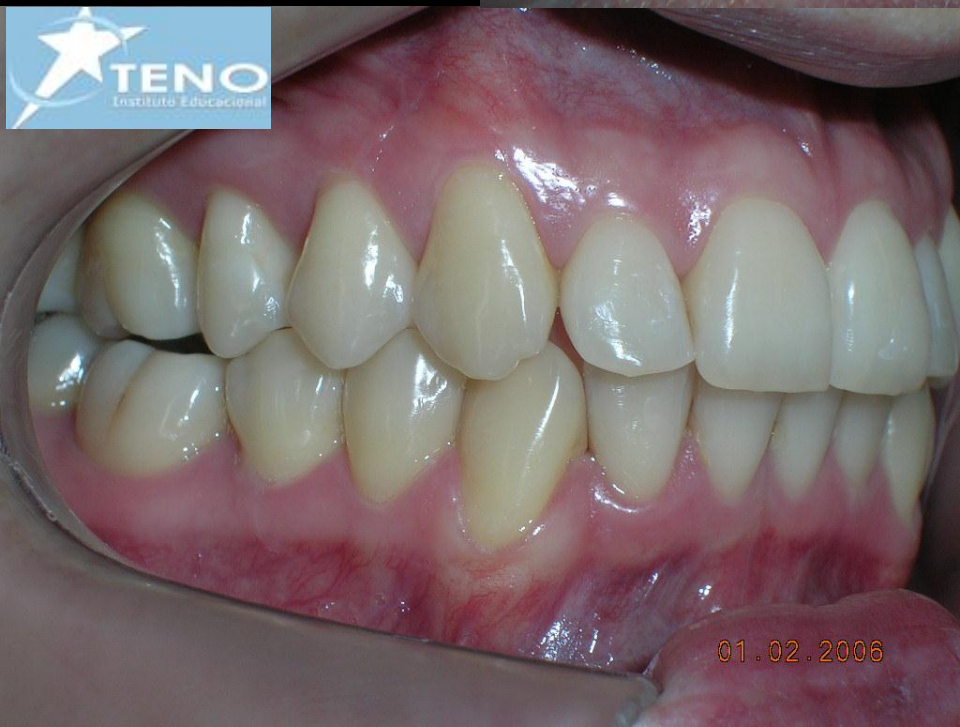
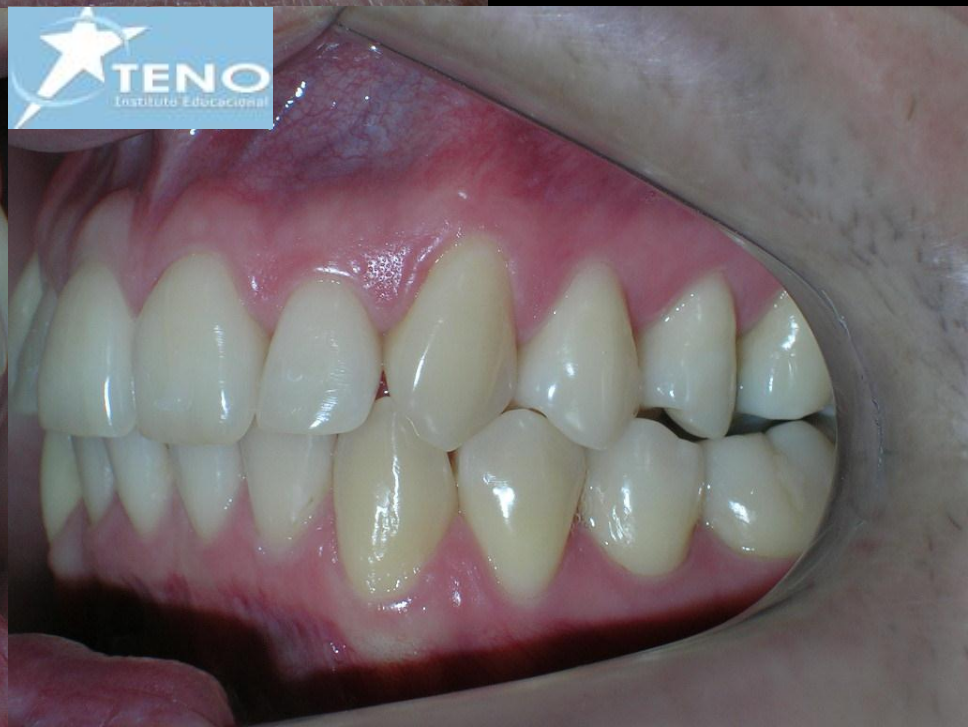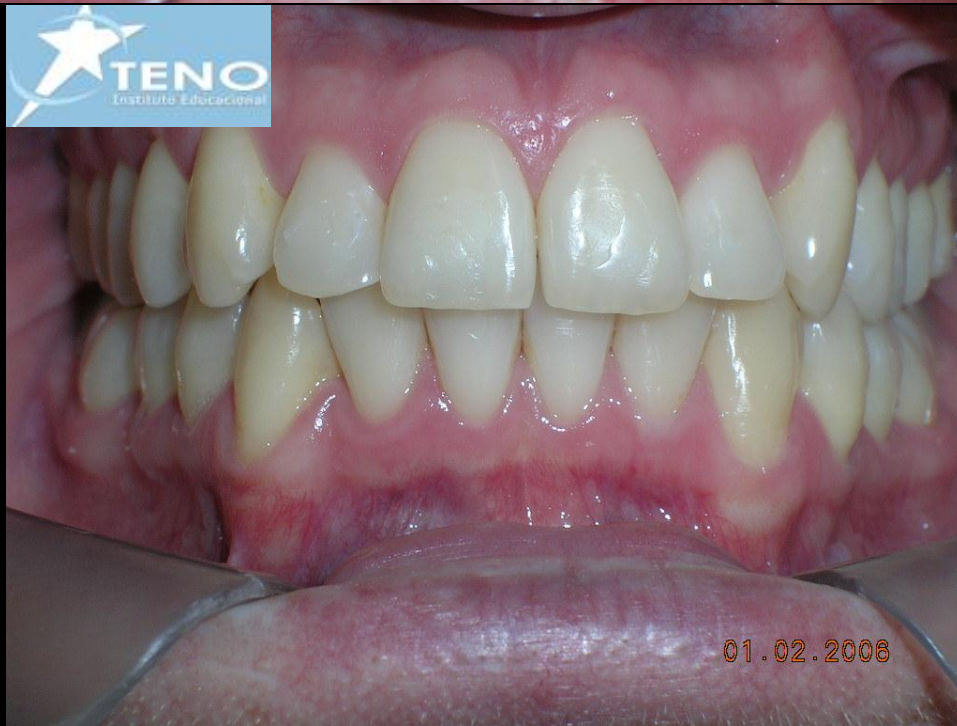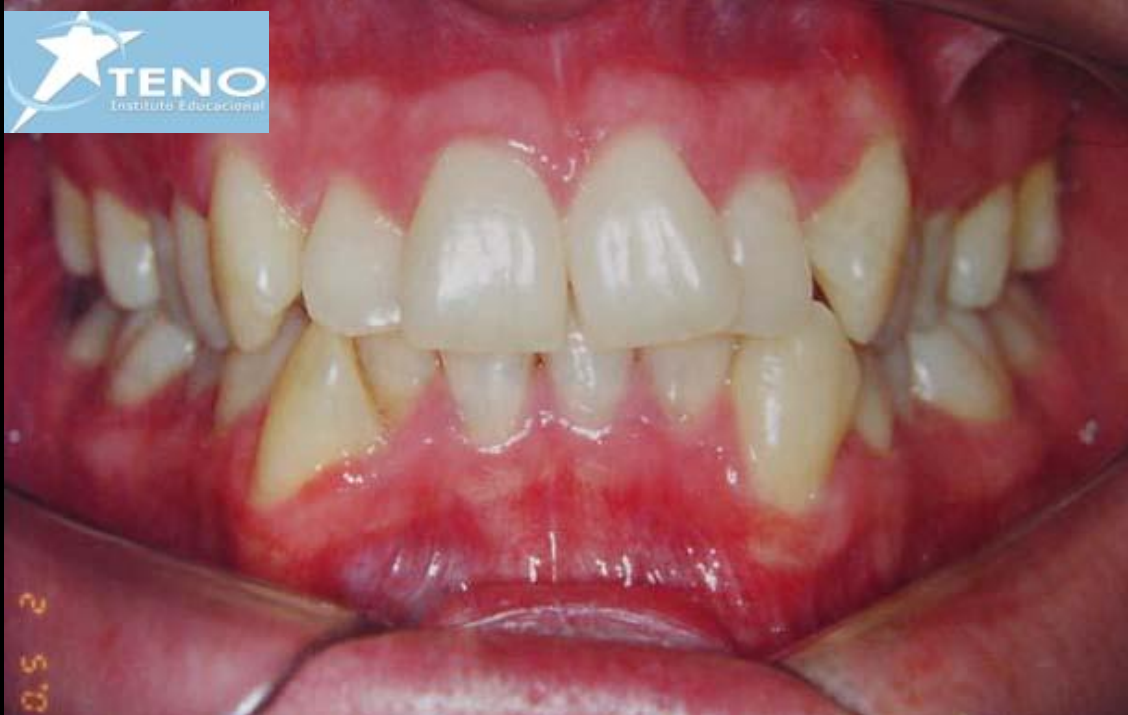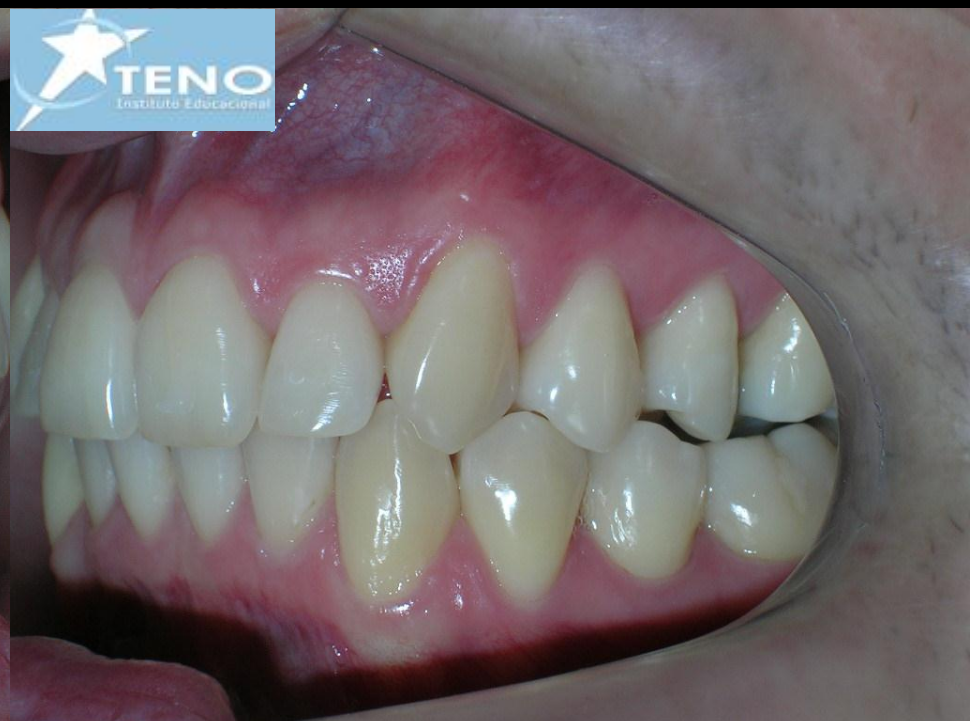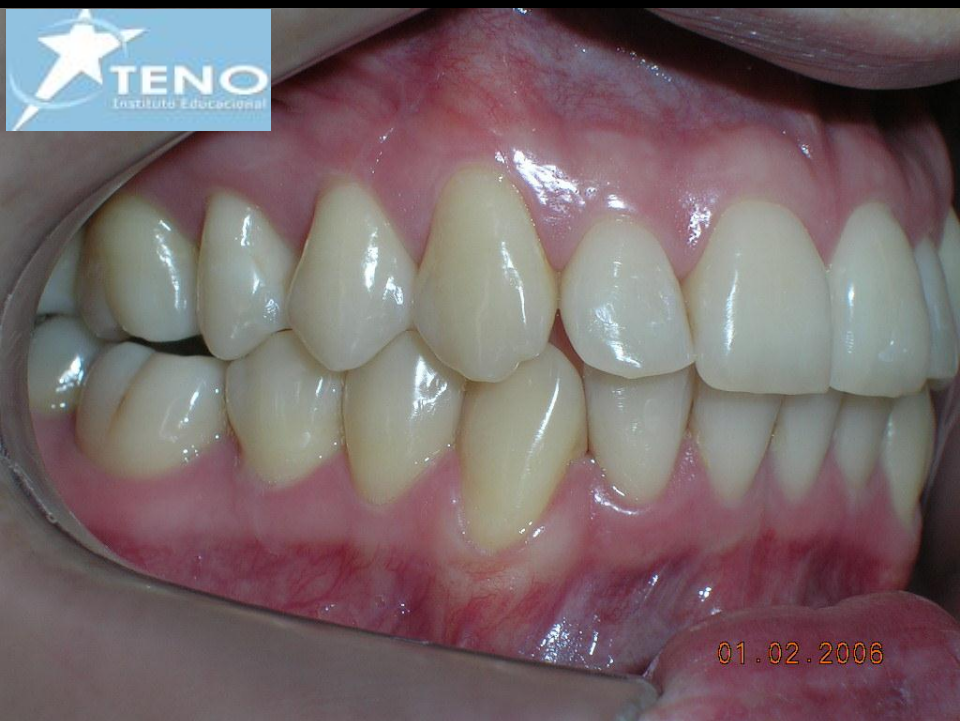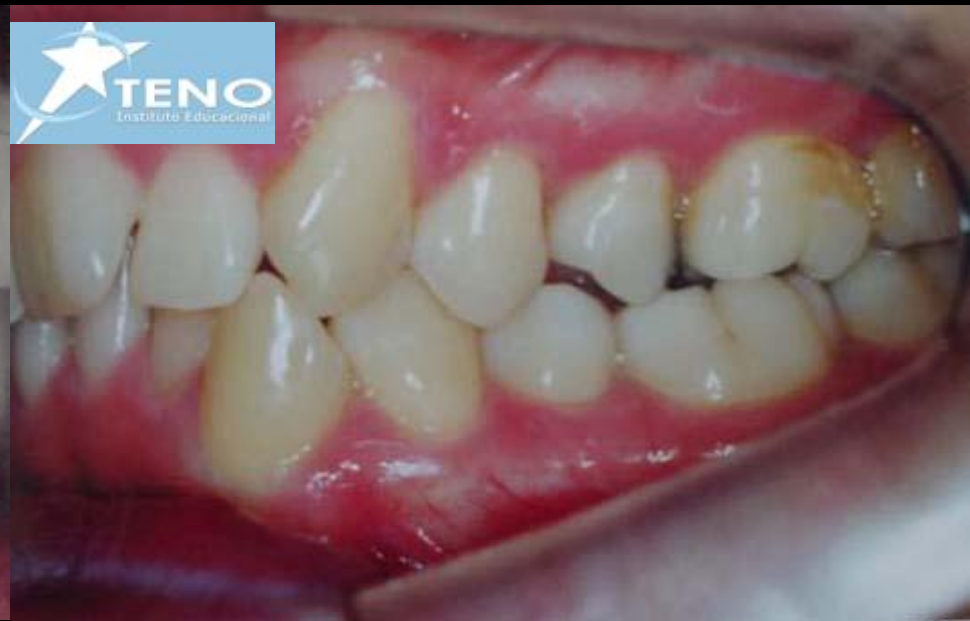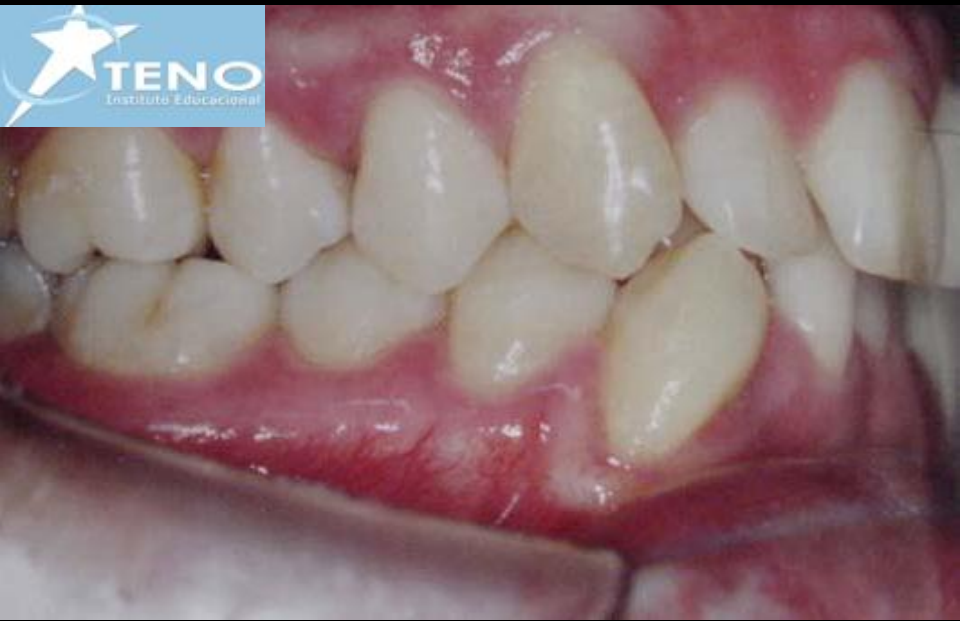01.02.2006



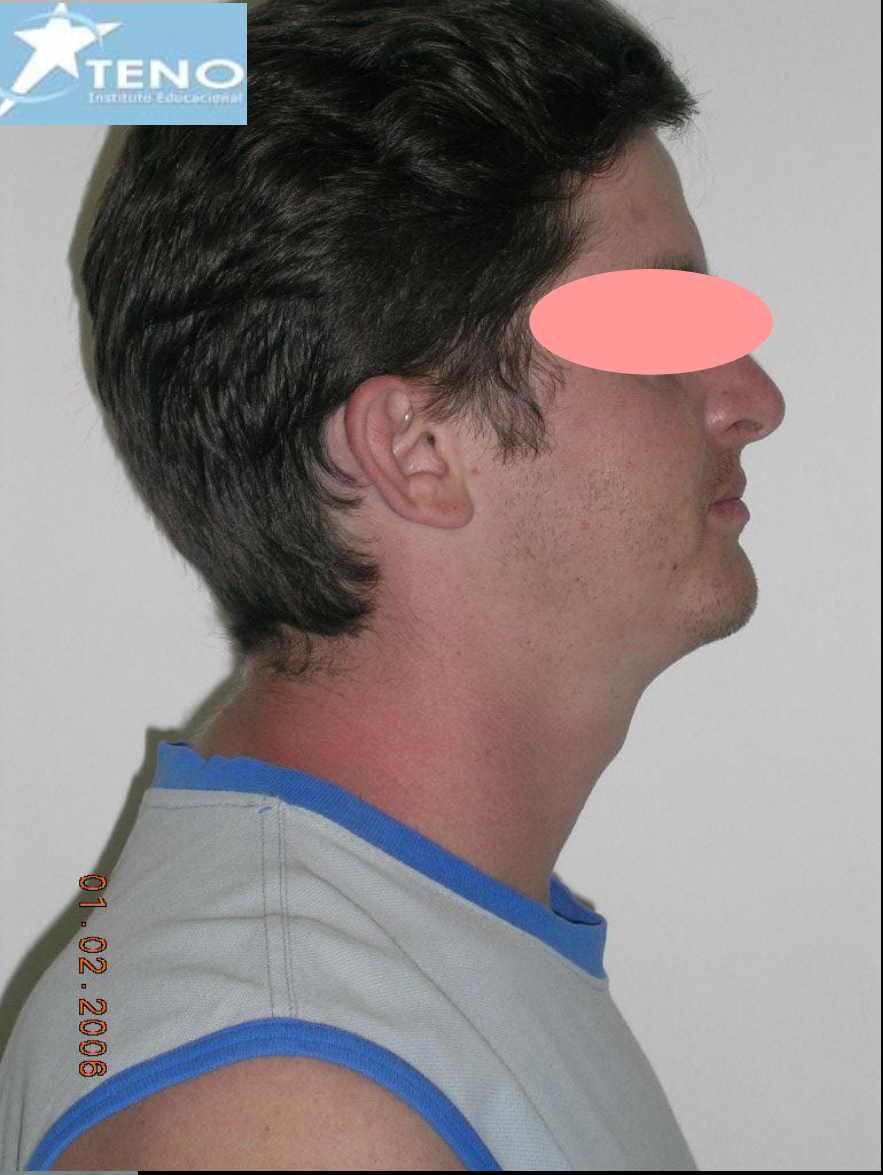01.02.2006





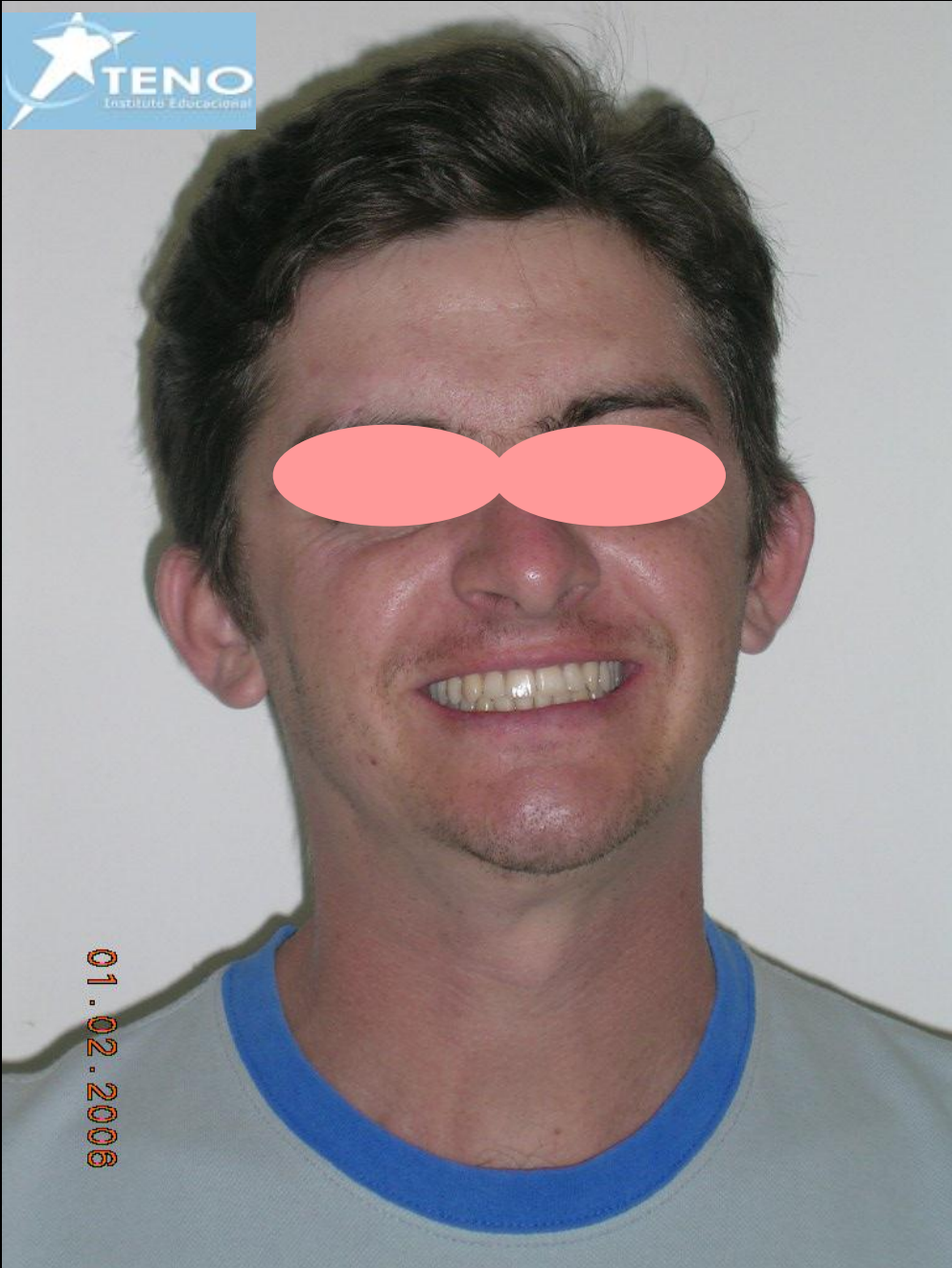

01.02.2006



01.02.2008

01.02.2008



01.02.2008